

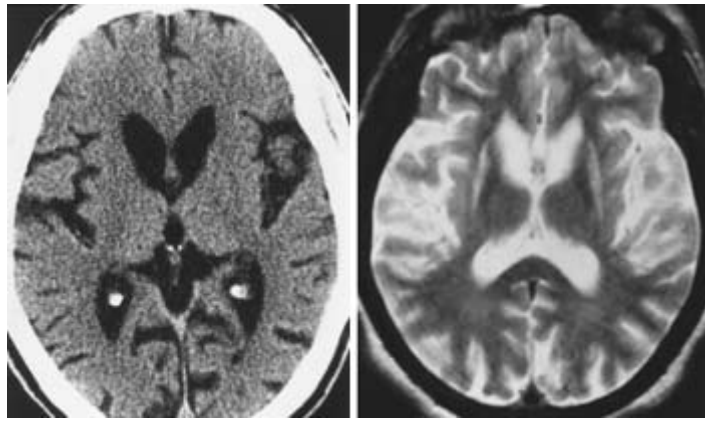
EANS/UEMS European examination in neurosurgery

Variants of questions with answers (compilation - Vyacheslav S. Botev,
Department of Neurosurgery, M.Gorky Donetsk National Medical University)

CASE HISTORIES IN CLINICAL NEUROLOGY

Case 1

A 45-year-old male with chorea and cognitive difficulties has the head CT scan and MRI shown below. His mother died at a nursing home, from a progressive neurologic disease. His uncle is in a mental institution.

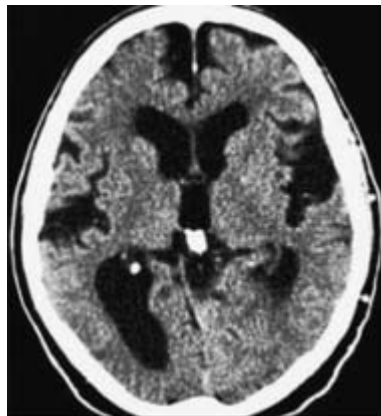

1. What is the imaging finding?
2. What is the most likely diagnosis?
3. What is the most useful test to confirm the clinical diagnosis?
4. Atrophy in the head of the caudate nucleus in patients with Huntington's disease affects the shape of which of the following?
 - A. Cerebellum
 - B. Lateral ventricle
 - C. Third ventricle
 - D. Lenticular nuclei
 - E. Temporal lobe
5. If a patient with Huntington's disease were to be exposed to L-dopa, which of the following would most likely be evoked?
 - A. Generalized seizures
 - B. Partial seizures
 - C. Intention tremor
 - D. Scanning speech
 - E. Writhing and jerking movements of the limbs

6. Which of the following movement disorders carries the highest risk of depression with suicide?
- A. Huntington disease
 - B. Parkinson disease (PD)
 - C. Progressive supranuclear palsy
 - D. Wilson disease
 - E. Gille de la Tourette syndrome

Case 2

A healthy 70-year-old male complains of difficulty walking, intermittent incontinence, and poor memory that has slowly progressed over the past 2 years. A complete metabolic work-up for dementia is negative, and he is told he has AD. His family tells you that after many months of struggling with his care at home, they have recently decided to place him in a nursing home. Before agreeing with the family, you order a head CT.



1. What does the head CT show?
2. Provide a differential diagnosis and the most likely diagnosis.
3. What are the main clinical criteria for the most likely diagnosis?
4. What is Evans' ratio?
5. What other conditions predispose to this diagnosis?
6. What diagnostic studies can confirm this diagnosis?
7. What are the limitations of these studies?
8. What treatment measures are available for this condition?
9. What are the main complications of these treatment measures?
10. Name some prognostic factors for the treatment of this condition.
11. Does the degree of ventricular enlargement correlate with symptoms?

Case 3

A 40-year-old man developed sudden-onset speech difficulty whilst at work and the following day became increasingly confused. He was seen by his GP later that day who found that he was unable to follow commands. There was no history of associated headache, fever, or weakness. There was no family history or past medical history of note. The patient was not taking any medication and denied illicit drug use.

On examination, the patient was afebrile, thin, confused, and agitated. The neck was not stiff. There was both expressive and receptive aphasia. Cranial nerves were normal with the exception of the presence of a hearing aid. The fundi could not be seen owing to lack of patient co-operation. The upper limbs were wasted proximally with increased tone on the right and although all 4 limbs were moving, the right appeared dyspraxic and the patient favoured the left. Lower limb power appeared full, reflexes were brisk and symmetrical and the right plantar was equivocal. Shortly after admission, the patient suffered two grand mal seizures.

Investigations showed: FBC, U&E, LFT, TSH, CK: normal.

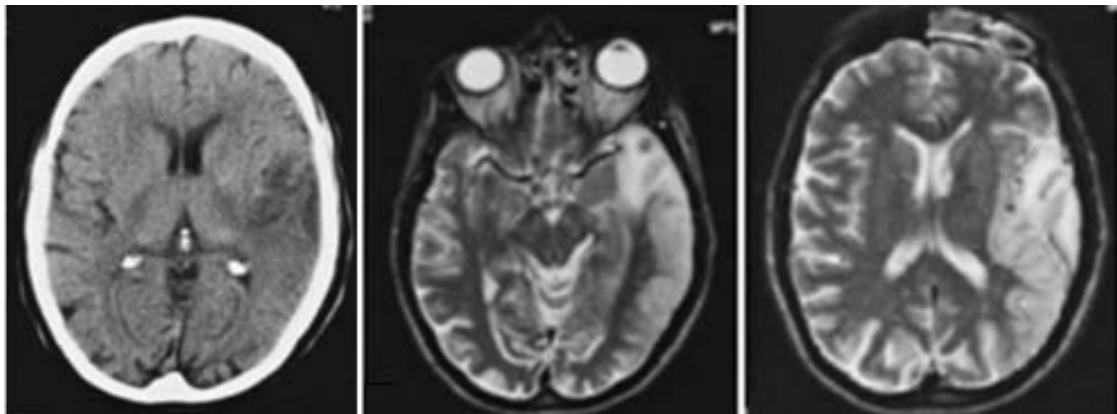
CRP 51mg/L, fasting glucose 6.3mm/L.

ANCA and ANA: negatives.

CSF: acellular, protein 1.2g/L, glucose 3.9mm/L, no organisms.

EEG: slow wave activity in the left temporal and occipital lobes.

CT and MRI brain scans are shown:



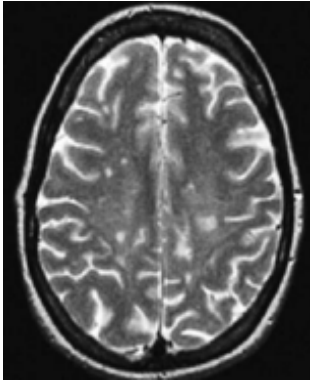
Questions

1. Give the differential diagnosis you would have considered before obtaining the investigation results.
2. What does the brain imaging show?
3. Which is the most likely diagnosis?
4. What are the clinical features of this condition?

5. What investigations would help in diagnosis?
6. Is there a definitive diagnostic test?

Case 4

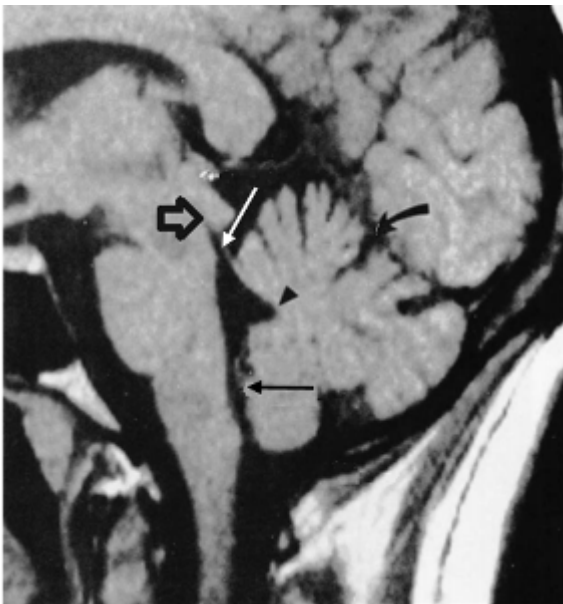
A 21-year-old woman presents with right arm loss of sensation that has been progressive over a few days. Her physician orders an MRI, which is pictured below. Which of the following is the most likely process?



- A. Ischemic
- B. Demyelinating
- C. Neoplastic
- D. Hemorrhagic
- E. Psychogenic

Case 5

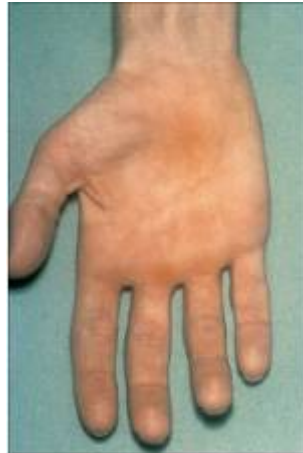In this MRI scan, the site most likely to produce a noncommunicating hydrocephalus when it is obstructed is identified by which of the following?



- A. Open black arrow
- B. Straight white arrow
- C. Curved black arrow
- D. Black arrowhead
- E. Straight black arrow

Case 6

A 58-year-old male presented with wasted hands bilaterally.



1. Give four causes of this presentation.
2. What features in the neurologic examination would help to distinguish these causes?
3. If there were no sensory abnormalities, list four possible causes and the investigation of choice for each.

Case 7

A 32-year-old woman presents with a one-year history of left-hand weakness and incoordination, numbness in per medial left forearm, and paresthesias in her left fifth digit when she rotates her head to the right. Her weakness temporarily worsens with overhead arm activity, including combing her hair and reaching for items. She denies sensory symptoms in the thumb or first two fingers. She is a slim woman with a long neck and poor posture. On examination, she has mild atrophy and weakness in both the median and ulnar innervated hand intrinsic muscles compared with the opposite hand, hypesthesia along the medial left forearm, and a positive Tinel sign with gentle tapping in the left supraclavicular space. Her radial pulse disappears in either arm when the arm is raised above her head.

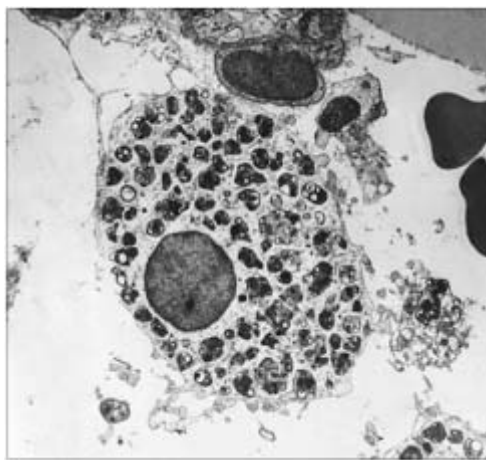
Questions

1. What is your differential diagnosis?
2. Describe the myotome and dermatome for C8, T1, and the lower trunk.
3. What diagnostic studies would you request to help confirm the diagnosis?
4. What are the different types of thoracic outlet syndrome?

5. What is the proposed pathophysiology of neurogenic thoracic outlet syndrome?
6. What are the treatment options?
7. What is the success rate of surgery for neurogenic thoracic outlet syndrome?

Case 8

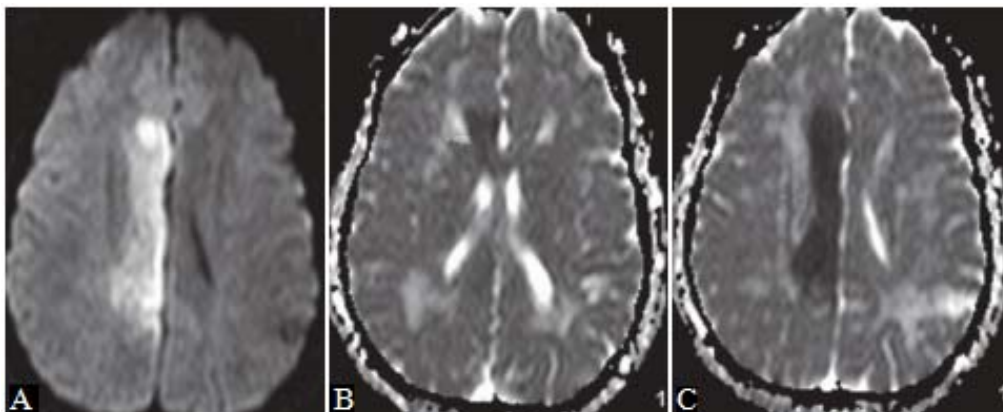
A 15-year-old female with cognitive decline for the last 3 years has on examination mild dystonia of her arms and vertical gaze palsy. The figure shows an electron microscopy of a bone marrow histiocyte. Her family history is negative.



1. What is the likely diagnosis?
2. What is the inheritance?
3. Is there a laboratory method for confirming the diagnosis?

Case 9

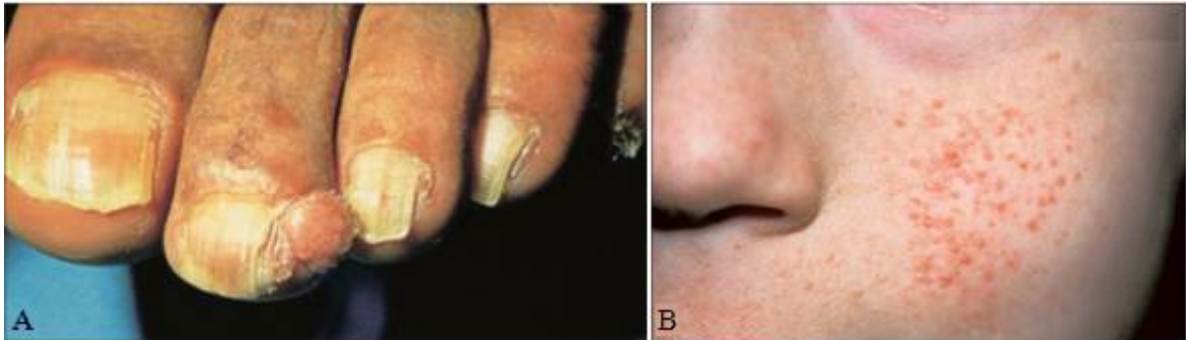A 28-year-old female with stroke.



1. Describe the findings on the imaging study.
2. What is the differential diagnosis?
3. What is your diagnosis?
4. Where does the vascular supply to the corpus callosum (CC) come from?
5. What the treating physician needs to know?

Case 10

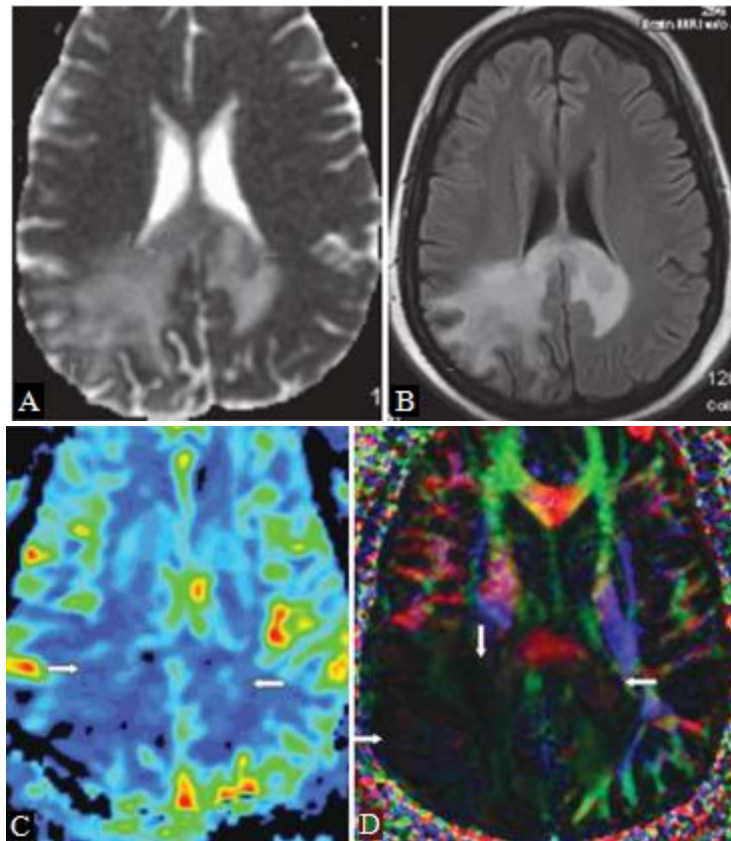
These two figures (A, B) show characteristic lesions of a specific neurogenetic disease.



1. Identify the lesions.
2. What is the diagnosis and typical clinical and pathologic features of this disease?
3. What is the inheritance pattern?
4. Is there a DNA test available to confirm the clinical diagnosis?
5. Which of the following is a major criterion for the diagnosis of tuberous sclerosis?
 - A. Subependymal giant cell astrocytoma
 - B. Vestibular schwannoma
 - C. Meningioma
 - D. Optic glioma
 - E. Neurofibroma

Case 11

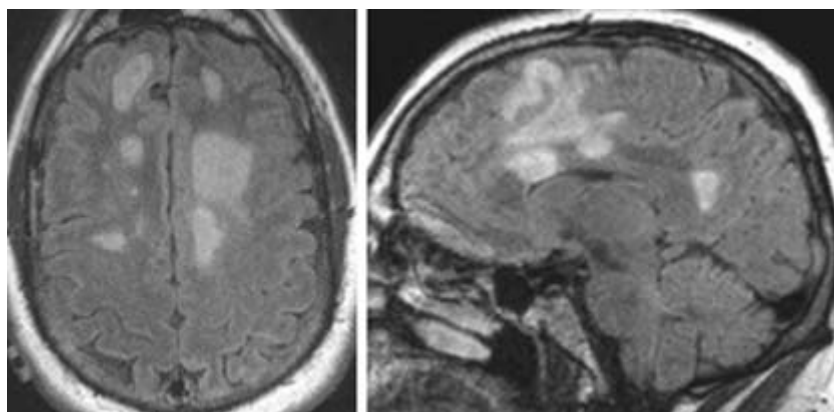
A 28-year-old female who presented with 6-month history of vertigo followed by headache, left arm and leg numbness, and left lower homonymous quadrantanopia.



1. Describe the findings on the imaging study.
2. What is the differential diagnosis?
3. What is your diagnosis?
4. What other lesion could be confused with the histology of umefactive demyelinating lesion (TDL)?
5. What the treating physician needs to know?

Case 12

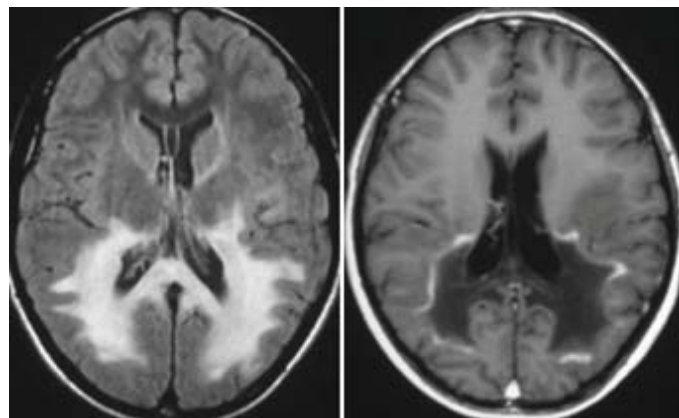
A 23-year-old male presents with numbness, muscle weakness, ataxia, and nystagmus.



1. What percentage of patients with multiple sclerosis present in childhood and adolescence?
2. What clinical and imaging factors might help differentiate demyelinating disease from a glioma?
3. What percentage of patients with multiple sclerosis present after 50 years of age?
4. What findings may be present in the CSF in patients with multiple sclerosis?

Case 13

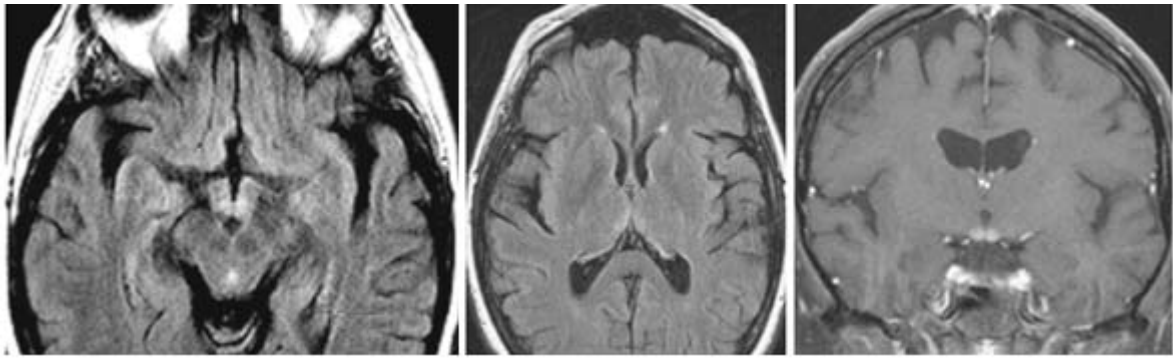
A 25-year-old male presents with muscle stiffness and paraparesis.



1. What is the characteristic MR imaging appearance of metachromatic leukodystrophy?
2. What do the areas of enhancement represent in this case?
3. How is adrenoleukodystrophy genetically transmitted?
4. What leukodystrophy results from a deficiency in the enzyme N-acetylaspartoacylase?
5. What is the differential diagnosis?

Case 14

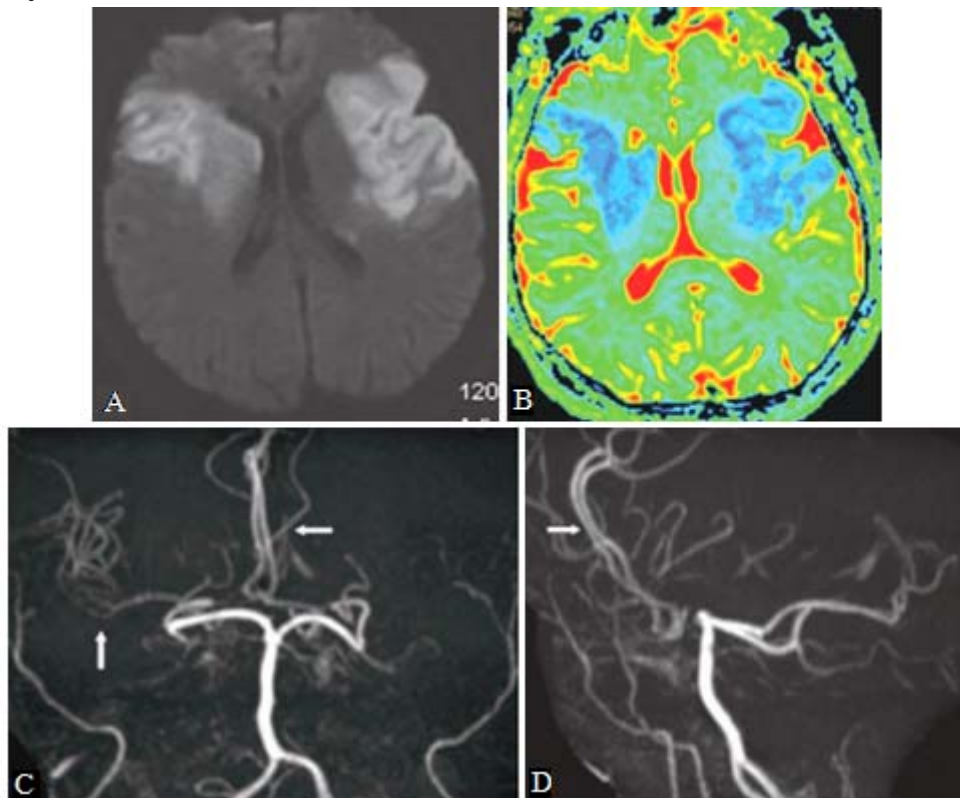
A 55-year-old male presents with tremor, nystagmus and gaze paralysis, confusion, delusions, and ataxia.



1. What are the imaging findings?
2. What is the best diagnosis?
3. What is the cause of this entity?
4. What vascular abnormalities can result in bithalamic signal alteration?

Case 15

A 62-year-old male with history of stroke. These images were obtained on the second day of admission.




1. Describe the findings on the imaging study.
2. What is the differential diagnosis?
3. What is your diagnosis?

4. How does blood get to the ACAs despite complete occlusion of bilateral ICA?
5. What the treating physician needs to know?

Case 16

A 24-year-old postdoctoral fellow with history of stroke brought by his family to see you. They stated that he eats only food on the right side of the plate, and fails to properly clothe and groom the left side of the body. They said that he is right handed. The patient was asked to circle all the A's. Only targets on the right are circled:

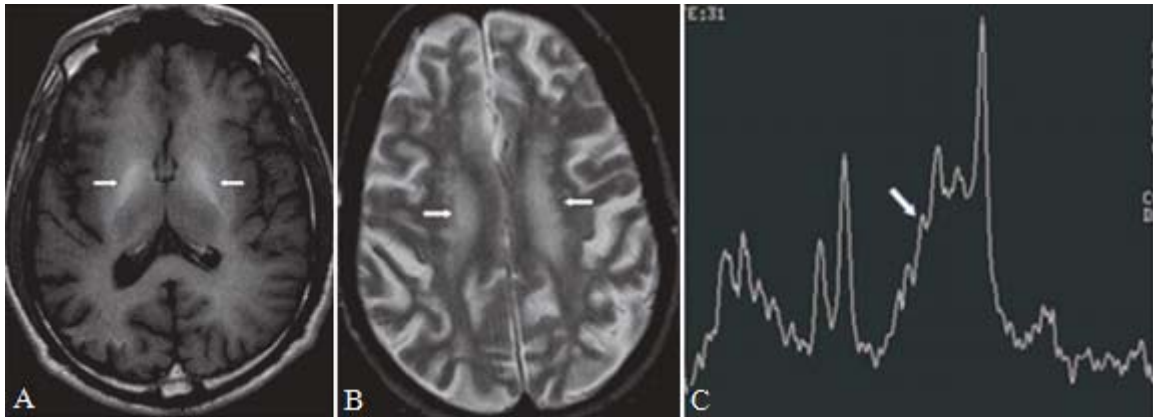


Where is the anatomical location of the lesion responsible for these vague behaviors?

- A. Left frontal lobe
- B. Left parietal lobe
- C. Right frontal lobe
- D. Right parietal lobe
- E. Both cerebral hemispheres

Case 17

Patient with known hepatic insufficiency with confusion.



1. Describe the findings on the imaging study.
2. What is the differential diagnosis?
3. What is your diagnosis?
4. Are there any other conditions than liver dysfunction that can cause manganese deposition in the brain?
5. What is the underlying mechanism of T2WI signal abnormalities?
6. What the treating physician needs to know?

Answers

Case 1

1. The CT and MRI shows atrophy of the caudate nuclei, which results in ballooning of the frontal horns of the lateral ventricles (“boxcar” ventricles). There may also be involvement of the putamen, which can atrophy. MR imaging shows signal changes in these nuclei. These changes may be hyperintense on T2W images which is believed to be related to gliosis; other cases show T2W hypointensity, which is likely related to iron deposition. Other major imaging findings include cortical atrophy.

2. This patient has Huntington’s disease (HD). HD is a neurodegenerative disorder characterized by involuntary movements, cognitive, and behavioral disturbances. There are adventitious movements and difficulties with the motor control of voluntary movements. The behavioral dysfunction presents with problems in planning, initiating, and completing tasks. Psychiatric disturbances can be the presenting symptoms. The average age at onset is 35–45 years, but onset can vary from childhood to old age. It is an autosomal dominant genetic disease. In this patient, the history of chorea, cognitive difficulties, and a family history of neurologic problems is very suggestive of HD.

3. There is a commercially available and highly specific DNA test. The gene for HD is on chromosome 4p16. The disorder is caused by an expansion of a CAG trinucleotide repeat in the HD gene. The normal repeat range is 6–27. Greater than 38 repeats is abnormal and will lead to symptoms of HD during a normal life span. The 36–38 repeat range is an intermediate one in which patients may or may not develop symptoms but their children are at risk for the disease. In the 28–35 repeat range patients will not develop symptoms, but their children are at risk for inheriting a larger expansion. The test detects the number of repeats in the HD gene. A positive test together with the clinical picture and the family history confirms the diagnosis.

4. The answer is B. Lateral ventricle.

As the caudate atrophies, the frontal tip of the lateral ventricle becomes increasingly rhomboidal in shape. The head of the caudate is usually atrophic early in the course of Huntington’s disease, and this will usually be evident by the time the patient is symptomatic, if not sooner. On MRI or CT scanning, the

head of the caudate gives the frontal and parietal components of the lateral ventricle its typical comma, or boomerang, appearance.

5. The answer is E. Writhing and jerking movements of the limbs.

Writhing and jerking movements of the limbs are part of the chorea that typically develops with Huntington's disease. Dopaminergic drugs, such as L-dopa, bromocriptine, and lisuride, may unmask chorea. This is inadvisable as a diagnostic technique because it may contribute to the premature symptom of chorea. Dopamine antagonists, such as haloperidol, may be used to suppress chorea, but also carry the risk of provoking tardive dyskinesia. Huntington's disease is characterized pathologically by loss of several neuronal types in the striatum (caudate and putamen). It has been hypothesized that the occurrence of dopaminergic-induced chorea in Huntington's disease is related to increased sensitivity of the dopamine receptors in the remaining striatal neurons, although there are abnormalities in several other neurotransmitters as well. Choreiform movements develop in a variety of other conditions; the one most similar to Huntington's disease is hereditary acanthocytosis.

6. A. Huntington disease.

Depression may complicate the course of a number of movement disorders. Among all of these, Huntington disease carries the highest risk of depression and suicide. Depression may affect half of the patients, with 30% meeting the criteria of major depression. Suicide is four to six times more common among Huntington disease patients than other depressed patients. In one study including Huntington disease patients and their relatives, the rate of death caused by suicide reached 7.3%. Depression may complicate the course of PD patients in approximately 40% of cases. Depression is seen in 20% to 30% of patients with the diagnosis of Wilson disease. Depression is less frequently seen in progressive supranuclear palsy and Gilles de la Tourette disorders.

Case 2

1. The head CT demonstrates modest hydrocephalus with enlargement of the lateral and third ventricles.

2.

- Normal pressure hydrocephalus (NPH) — most likely.
- Differential diagnosis of dementia includes (mnemonic is "CITTEN DIVA,")

more common conditions are in boldface).

- Congenital/developmental: Huntington disease.
- Infectious: syphilis, human immunodeficiency virus (HIV), meningitis, herpes encephalitis.
- Traumatic: posttraumatic dementia, concussion, chronic subdural hematoma, hypoxia.
- Tumor: metastatic disease, carcinomatosis.
- Endocrine: Addison disease, Cushing syndrome, diabetes mellitus, thyroid and parathyroid disease, renal failure.
- Neurologic: Alzheimer disease, Parkinson, Pick dementia.
- Drugs/medications: alcohol induced, vitamin B12 or folate deficiency, pellagra, vitamin B1 deficiency.
- Inflammatory: multiple sclerosis, prion disease.
- Vascular: diffuse small vessel disease, stroke.
- Acquired and other: depression, psychosis.

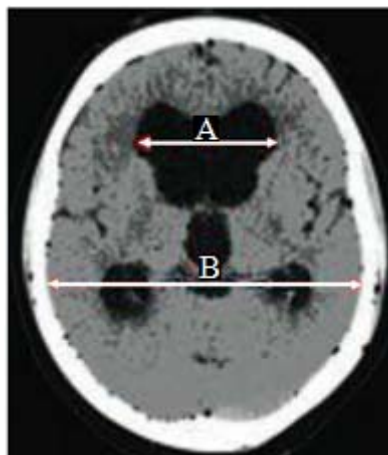
3.

• The Adams triad includes

- Ataxia: precedes other symptoms, wide based, “glued to the floor,” difficult initiation of gait
 - Dementia: memory, bradyphrenia, bradykinesia
 - Urine incontinence
- Other criteria include male sex, age greater than 60 years, communicating hydrocephalus, normal pressure on lumbar puncture

4. The ratio of the maximum width of the frontal horns to the maximum width of the inner table of the cranial vault. If the ratio is greater than 0.3, then there is a greater likelihood of hydrocephalus.

Evans' ratio = A/B



5.

- Postsubarachnoid hemorrhage
- Posttrauma
- Postmeningitis
- After posterior-fossa surgery
- Tumor, carcinomatous meningitis
- Alzheimer disease
- Aqueductal stenosis

6. Diagnostic studies are outlined below:

- CSF “tap” test by performing a lumbar puncture (LP) with removal of 40 to 50 cc of CSF followed by assessment of improvement of cognitive abilities.
- Serial LP.
- Continuous intracranial pressure (ICP) monitoring.
- Lumbar drain placement.
- Radionucleotide cisternography.

7. Limitations of the studies include the following:

- CSF “tap” test has a poor sensitivity (26–62%).
- LP : An opening pressure (OP) greater than 10 (but less than 18 mm H₂O) is associated with a higher response rate to shunting.
- Continuous ICP monitoring: Normal OP, but pressure peaks greater than 270 mm H₂O or recurrent B waves are predictors of better prognosis with shunting.
- Radionucleotide cisternography: Persistence of ventricular activity in a late scan (after 48–72 hours) is associated with a 75% chance of improving with shunting (this is also the case if the ratio of ventricular to total intracranial activity (V/T) is greater than 32%).

8.

- Ventriculoperitoneal shunt
 - Medium-pressure valve shunt.
 - Programmable shunt.
- Other shunt types: ventriculopleural or ventriculoatrial.
- Third ventriculostomy (only in cases of obstructive hydrocephalus).

9.

- Complication rate of shunting in NPH is 30–40%.

These include

- Subdural hematoma 8–17%.
 - Higher rate if the patient is older or if a low pressure valve is used.
 - Two thirds resolve spontaneously; one third needs evacuation and shunt tying.

- Shunt infection, obstruction, or disconnection (10–31%).
- Intraparenchymal hemorrhage.
- Seizure (4%).

10.

- The most likely symptom to improve is incontinence, then ataxia, and lastly dementia.
- There is a better response rate if the gait impairment is the primary symptom.
- Long-term response rate is as high as 75%.
- The response is better if the symptoms are present for a shorter time.
- Some patients (e.g., with Alzheimer disease) will improve for a brief period and then worsen again.

11. To our knowledge the acuity of hydrocephalus correlates with symptoms instead of degree of hydrocephalus. The degree of hydrocephalus is a better sign of cortical atrophy.

Case 3

1. The differential diagnosis in this case is wide and, depending on the significance placed on the apparent wasting of the proximal upper limb muscles, could include any of the following disorders:

Vascular: Stroke, Venous sinus thrombosis, Subdural hematoma.

Infectious: HSV, HIV, TB, Cryptococcus, aspergillus, Toxoplasma, Cerebral abscess, Whipple's disease.

Inflammatory: Sarcoid, Connective tissue disease, Acute disseminated encephalomyelitis (ADEM), Vasculitis, Hashimoto's encephalitis.

Metabolic: Hypoglycaemia, Electrolyte disturbance, Mitochondrial disease.

Neoplastic: Space occupying lesion, paraneoplastic syndrome.

The clinical features of this case indicate a stroke-like episode (sudden onset of speech difficulty) followed by encephalopathy (confusion). The stroke-like episode suggests a vascular etiology but other non vascular disorders may present with sudden onset focal deficits and should be considered where there are atypical clinical features, such as an absence of vascular risk factors, or unusual imaging findings.

2. The CT brain shows basal ganglia calcification and a hypodense region in the left temporal lobe. The T2-weighted MRI brain shows a primarily cortical

hyperintensity in the left temporal parietal region not typical of a middle cerebral artery branch infarction.

3. The diagnosis is mitochondrial encephalopathy, lactic acidosis, and stroke-like episodes (MELAS).

4. MELAS should always be considered in any young to middle-aged patient with a stroke in the absence of any other obvious cause, particularly if the stroke is in the occipital region and is associated with seizures. MELAS is one of the multisystem disorders associated with mutations of mitochondrial DNA inherited through the maternal line. Mitochondrial DNA encodes proteins involved in the respiratory chain. The phenotypes of the various mitochondrial diseases are characteristic but often overlap. Cardiomyopathy, proximal muscle weakness (as in this case), progressive external ophthalmoplegia, myoclonus, ataxia, exercise intolerance, pigmented retinopathy, and ovarian and testicular failure, are typical features.

MELAS presents in childhood or young to middle-aged adults often with focal neurological episodes that usually affect the occipital lobes, and may be triggered by infection. Hemianopia, cortical blindness, hemiparesis and aphasia may occur. Sudden onset headache, episodic vomiting and seizures are common. Ultimately, the patient becomes demented and often cortically blind. Associated clinical features includes short stature, sensorineural deafness, mitochondrial myopathy, migraine, diabetes mellitus, peripheral neuropathy, learning disability, and salt and pepper retinopathy. Owing to phenotypic and genotypic heterogeneity, relatives of an index patient may not present with MELAS but rather with one of the other mitochondrial syndromes. The cause of the acute focal cerebral dysfunction is unclear but large vessel occlusion does not occur. Metabolic defects and structural changes in small vessels have been proposed.

5. The following investigations are useful in diagnosis: Blood and CSF lactate level, Muscle biopsy, Brain imaging.

Blood and CSF lactate levels are often increased as seen in this patient [3.3mmol/L (normal range 0.5–2.0mmol/L) and 6.5mmol/L (normal <2.5mmol/L) respectively] owing to dysfunction of the respiratory chain, but similarly elevated CSF lactate levels may be seen after acute stroke of other aetiology, seizures, meningitis, and subarachnoid haemorrhage. Serum CK is often normal. Muscle biopsy usually shows a mitochondrial myopathy with ragged red fibres shown using Gomori's trichrome stain and large numbers of abnormal

mitochondria on electron microscopy, although the latter may be normal.

Brain imaging shows basal ganglia calcification (as seen in this patient) in 50% of cases, always involving the globus pallidus. CT may show low density areas in the grey and white matter mainly in the occipital and parietal lobes and cerebellum with enhancement and mass effect in the acute phase. T2-weighted hyperintensities in the cortex are seen on MRI which may disappear on subsequent scans. Cerebral and cerebellar atrophy are seen and fourth ventricular enlargement may occur early. The lesions visible on brain imaging are often described as infarcts but do not correspond to the territories of the main cerebral arteries.

6. The diagnosis of MELAS can be confirmed by mitochondrial DNA analysis of white cells or skeletal muscle. A mitochondrial DNA point mutation at position 3243 within the tRNA^{Leu} (URR) encoding gene is most commonly seen. This mutation is always heteroplasmic in that wild type DNA is also present, suggesting that wild type DNA is required for foetal viability. However, not all patients have known mutations and some of the known mutations may be found in patients with other mitochondrial syndromes. Further, relatives who carry the mutation may be asymptomatic and mutations can be found in the normal population.

Case 4

The answer is B. Demyelinating.

The history and MRI are consistent with a demyelinating process, such as acute disseminated encephalomyelitis (ADEM) or multiple sclerosis. The MRI shown is a T2-weighted image. Several areas of abnormal high signal are apparent. Magnetic resonance imaging depends primarily upon the water content of tissues, but it can be customized to look at more specific properties of tissues. A variety of methods are available for affecting the information produced by and analyzing the information generated by MRI. The T2-weighted image is not specific for demyelination, but it is useful in following changes in plaques of demyelination, an application that has been used in studies of agents useful in the management of multiple sclerosis.

Case 5

The answer is A. Open black arrow.

The open black arrow denotes the aqueduct of Sylvius, which connects the third ventricle with the fourth ventricle. This sagittal view of the lower part of the brain provides a high-resolution view of the posterior fossa. What appears to be a connection between the most inferior aspect of the fourth ventricle and the cisterna magna (at the straight black arrow) is an artifact. This is the obex of the fourth ventricle, and there is a complete roof over this ventricle, which communicates with the subarachnoid space through the foramen of Luschka and Magendie.

Case 6

1. Wasting of the small hand muscles indicates a lower motor neuron condition. It can be caused by conditions affecting any part of this pathway from the peripheral nerve to the anterior horn cell. (1) Neuropathy (peripheral sensorimotor or motor neuropathy: hereditary, e.g. HMSN; acquired, e.g. CIDP. (2) Bilateral brachial plexopathy. (3) Neuronopathy (i.e. anterior horn cell): MND; ALS. (4) Myelopathy (syringomyelia): a centrally expanding lesion involving the anterior horn cells responsible for the small hand muscles.

2. The features associated with the wasted hand muscles will help either to localize the lesion or to indicate a possible diagnosis. As well as involvement of the lower motor neuron, as indicated by the wasting of the muscles, additional abnormalities in other parts of the neurologic examination will narrow down the differential diagnosis. Consider abnormalities in the cranial nerve examination, changes in tone, patterns of weakness, the pattern of the reflexes and plantar responses, and the sensory examination: (1) bulbar involvement (MND/syringobulbia); (2) marked fasciculations (MND); (3) spasticity, e.g. MND and in the legs in syringomyelia; (4) pattern of weakness, e.g. distal in peripheral neuropathy and pattern of particular part of the brachial plexus; (5) reflexes and plantar responses, e.g. it may be brisk in MND with extensor plantars, reduced or absent in neuropathy and plexopathy, and reduced or absent in arms and brisk in legs in syringomyelia; (6) sensory abnormalities, e.g. absent in MND, glove and stocking in peripheral neuropathy, and a cape distribution of pain and temperature loss (spinothalamic tracts) and intact joint and two-point sense (posterior columns) – so-called dissociated sensory loss.

3. The causes of a pure motor syndrome causing wasting of the small hand muscles are few – either a neuronopathy or a motor neuropathy. In this context, MND is the most likely neuronopathy. The causes of a pure motor neuropathy are also limited and usually one of the following: MMNCB/CIDP, lead neuropathy, or neuropathy secondary to acute intermittent porphyria. The investigations are as follows: for MND, neurophysiology (normal NCS with denervation on needle EMG); for MMNCB, neurophysiology (evidence of conduction block on NCS which may be proximal); for lead poisoning, 24-hour urinary lead; for acute intermittent porphyria, urinary urobilinogen and porphobilinogen.

Case 7

1. Considering that her neurologic examination localize her pathology to the lower trunk, the working diagnosis would be neurogenic thoracic outlet syndrome. The differential diagnosis for neurogenic thoracic outlet includes cervical radiculopathy, carpal tunnel syndrome, ulnar nerve entrapment at the elbow, motor neuron disease, and a Pancoast tumor.

2. Together, C8 and T1 innervate all of the hand intrinsic musculature via both the ulnar and median nerves (they also provide contribution to some more proximal muscles). Classically, these patients have paresthesias and numbness along the medial forearm.

3. An apical lordotic radiograph of the cervical spine should reveal any cervical ribs or “beaked” C7 transverse processes. Magnetic resonance imaging (MRI) with and without contrast of the brachial plexus (which should include the cervical spine) is ordered to exclude a herniated disc, foraminal stenosis, and tumors.

Although frequently normal in mild cases, electrodiagnostic studies can reveal denervation in both ulnar and median innervated hand muscles (e.g., first dorsal interosseous and abductor pollicis brevis, respectively) and perhaps an absent nerve action potential from the medial antebrachial cutaneous nerve.

4. Thoracic outlet is categorized as neurogenic, vascular, or disputed.

Neurogenic and vascular thoracic outlet are both quite rare; the disputed type is much more common.

Neurogenic thoracic outlet syndrome requires clear demonstration of objective neurologic finding on examination or diagnostic tests, including atrophy, electrodiagnostic testing abnormalities, a cervical rib, and/or focal nerve

swelling on MRI.

If no objective findings are present, the patient should be observed for their subsequent development.

5. Most experts believe that accessory ligaments and/or fascial bands related to a cervical rib or “beaked” C7 transverse process compress and distort the brachial plexus in patients with neurogenic thoracic outlet syndrome. It remains controversial whether the anterior scalene, per se, is responsible for nerve entrapment.

6. For patients with mild symptoms and signs, posture training and a trial of physical therapy may lead to improvement. If atrophy and/or weakness are present, then surgical decompression of the brachial plexus is indicated.

Once profound and chronic atrophy is present, however, the chance of surgical decompression causing a substantial improvement is unlikely. Therefore, early treatment is optimal.

An anterior suprascapular exposure of the brachial plexus is the preferred approach by neurosurgeons in patients with neurogenic thoracic outlet syndrome

7. If preoperatively the patient only has provocative symptoms (e.g., with overhead arm use), and only minimal signs of weakness and atrophy (i.e., mild cases), then surgical decompression leads to improvement in 85–90% of patients. When significant atrophy and weakness are present (moderate-to-severe cases), the chance of partial improvement is approximately two-thirds.

Case 8

1. The likely diagnosis is Niemann–Pick disease (NPD) type C. This is a neurometabolic disorder characterized by cognitive and behavioral decline with vertical supranuclear ophthalmoplegia and ataxia. Involuntary movements, seizures and pyramidal signs are other later features. Hepatosplenomegaly is present, but less severe than in NPD types A and B. NPD type A is a severe infantile neurogenetic disorder with hepato-splenomegaly. NPD type B has no neurologic involvement, a later onset of hepato-splenomegaly and survival into adulthood.

2. The inheritance pattern for NPD type C is autosomal recessive.

3. The biochemical defect is an abnormality in cholesterol transport, leading to the accumulation of sphingomyelin and cholesterol in lysosomes. The laboratory

method for confirmation of NPD type C is measuring intracellular cholesterol esterification and filipin staining of free cholesterol in cultured skin fibroblasts. This testing is commercially available and confirms the clinical diagnosis of NPD type C. NPD types A and B are diagnosed by marked sphingomyelinase deficiency, which is normal in type C. The bone marrow in types A, B and C show the characteristic lipid laden phagocytic foam cells or Niemann–Pick cells.

Case 9

1. (A) Axial DWI through the body of corpus callosum. There is diffuse hyperintensity through the CC and cingulum on the right. ADC maps through the genu (B) and body (C) of the CC. There is low ADC in the genu and through the entire body of the CC and cingulum on the right.
2. CC infarct, toxic leukoencephalopathy (LE), anterior cerebral artery territory infarct.
3. CC infarct (right anterior cerebral artery [ACA] territory infarct).
4. The rarity of CC infarct is due in part to its extensive collateral arterial vascular network deriving from three main arterial trunks. The cranial (anterior) segment of the CC is supplied by the subcallosal and medial callosal arteries from the anterior communicating artery. The pericallosal artery which is a branch of the ACA is most often the main vascular supply to the body of CC. The caudal aspect (splenium) of the CC receives supply from the posterior pericallosal artery, a branch of the posterior cerebral artery. The vessels give penetrating branches that arise almost perpendicular to the parent vessels which perhaps protect the CC from thromboembolic processes. The bulk of the supply is from the ACA. Isolated ACA territory infarcts are rare accounting for a very small percentage of all intracranial infarcts.
5.
 - Location of infarct; to determine possible cause and arterial territory involved.
 - Other associated infarcts or lesions.
 - Demyelination may be a difficult entity to distinguish from infarct in the CC.

Comment

Depending on the cause, CC infarct would be focal or diffuse. Like all infarcts, it restricts diffusion (hyperintense on DWI and hypointense on ADC maps) in

the acute phase with local mass effect but no contrast enhancement. The appearance mimics toxic LE. The infarct here is large with associated parasagittal right frontal lobe infarct. Focal mass-like and contrast-enhancing infarct would resemble a neoplasm or a demyelinating lesion. Presence of other changes such as WM lesions, large arterial territorial infarcts, and the clinical history may help in sorting out the differential diagnoses. In the chronic phase, CC infarct shows atrophy, ex vacuo dilation of the ventricle along with hyperintensity on FLAIR and T2WI. MRA or CTA may be useful in evaluating the vascular structures. Both the CTA and the MRA in this patient showed extensive vasculopathy both intracranially and extracranially.

Infarcts of the CC are rare. They are more common in the splenium than the body and anteriorly presumably due to higher frequency of posterior circulation infarcts compared to ACA territory infarct. They are more common in the elderly particularly patients with diabetes and hypertension due to diffuse atherosclerotic changes. Other cases include thromboembolic phenomenon, atherothrombotic phenomenon, vasculitis, vasculopathy, Susac syndrome, and watershed phenomenon. Clinical presentation may include confusion, neuropsychiatric symptoms, and specific syndromes of alien hand syndrome or disconnection syndrome, paraparesis, and gait disturbances.

Case 10

1. The lesions seen in the figures are a subungual fibroma (A) and facial angiofibroma (B).
2. This patient has tuberous sclerosis (TSC). TSC is a genetic disease that presents with abnormalities of the skin (hypomelanotic macules, shagreen patches, facial angiofibromas, subungual fibromas), brain (cortical tubers and subependymal nodules), kidney (angioliipomas and cyst), heart (rhabdomyoma and arrhythmias). Seizures are a very frequent finding and at least 50% of patients have developmental delay or mental retardation.
3. The inheritance pattern is autosomal dominant. The offspring of an affected individual are at 50% risk of inheriting the TSC gene. Two-thirds of cases represent new mutations. Variable expression is common.
4. There is no commercially available DNA test. Molecular testing is available on a research basis only. There are two genes known to cause TSC. The TSC1 gene at chromosome 9q34 and the TSC2 gene at chromosome 16 are each

responsible for about 50% of the cases. Some sporadic cases probably involve another unknown gene.

5. A. Subependymal giant cell astrocytoma.

Tuberous sclerosis complex (TSC) arises from abnormal cellular differentiation, proliferation, and neuronal migration. It affects the brain (cortical and subcortical tubers, subependymal nodules, and giant cell astrocytomas), kidney, skin (hypomelanotic macules, shagreen patches, facial angiofibromas, and periungual fibromas), eye (retinal hamartomas), heart, and to a lesser extent other organs. The Tuberous Sclerosis Complex Consensus Conference divided the criteria for diagnosis into major and minor features. The major features include cortical tuber, subependymal nodule, subependymal giant cell astrocytoma, and skin changes, as mentioned above.

Case 11

1. (A) Axial DWI with ADC map through the corpus callosum (CC) and bilateral forceps major showing confluent asymmetric bilateral hyperintensity larger on the right than left crossing the splenium of the CC. There is involvement of the subcortical U fibers on the right. Some areas of subtle restricted diffusion are seen within the splenium of CC.

(B) Axial FLAIR through the same level showing splenium and bilateral forceps major confluent hyperintensity surrounding isointense core extending into the subcortical region on the right. There is no significant mass effect.

(C) Axial MRI perfusion relative Cerebral Blood volume (rCBV) map through the lesion showing low blood volume in the splenium and bilateral forceps major (arrows).

(D) Axial DTI color orientation map through the splenium showing disruption of fiber tracts with reduced FA in the splenium, bilateral forceps major, and the right posterior corona radiata (arrows).

2. Demyelinating process, lymphoma, butterfly glioma.

3. Tumefactive demyelinating lesion (TDL).

4. TDL may be misinterpreted as a neoplasm given its hypercellular nature and the frequent presence of atypical reactive astrocytes and mitotic figures.

5.

- Is this a single lesion or are there other lesions that may suggest MS?

- Other imaging studies that may narrow the list of differential diagnosis include MR spectroscopy, MRI of the spinal cord, and MR of the orbits in the presence of visual disturbance to exclude other forms of demyelination

Comment

MR findings of demyelination includes white matter (WM) T2 hyperintensity anywhere in the brain including the CC, minimal surrounding edema and mass effect, nodular, patchy, incomplete ring, and arc patterns of contrast enhancement on post-contrast T1WI. However, contrary to popular belief, TDL can be associated with mass effect and edema. Diffusion restriction could be subtle but not common and usually indicates acute lesions. Low relative blood volume and flow on perfusion studies have been reported in demyelination. The definition of “tumefactive demyelination” is not consistent in the literature and may refer to various combinations of the following: WM location, large size (>2 cm), little mass effect or edema, and/or typical enhancement patterns (nodular, patchy, thin open or incomplete ring, heterogeneous). The butterfly pattern fits any of the listed differential diagnoses. Butterfly glioma tends to be necrotic and has a thick irregular ring contrast enhancement with surrounding large vasogenic edema and increase blood flow and volume on perfusion studies. Lymphoma on the other hand is highly cellular and may show restricted diffusion and avid contrast enhancement. Necrosis is not a component of lymphoma except in the setting of HIV. It has been suggested that NCCT may be able to differentiate TDL from GB and lymphoma on the basis of attenuation pattern on CT; lymphoma is usually hyperdense.

Cerebrospinal fluid (CSF) analysis prior to biopsy showed minimal increase in protein and an increase in IgG synthesis rate. There were no pleocytosis or oligoclonal bands. Bacterial, viral, and fungal studies were negative. MRI of the cervical and thoracic spine was normal. The diagnosis was made by stereotactic brain biopsy through the right parietal lesion. TDL of the central nervous system can be solitary or multiple. In the presence of preexisting demyelinating lesions such as multiple sclerosis (MS) the diagnosis may be easy. Dissemination in time and space is necessary to convert to diagnosis of MS.

Scrutinization of the history and prior imaging if available becomes important in this regard. TDL has been described rarely in association with astrocytoma. Solitary TDL was preceded the appearance of lymphoma, and therefore, longitudinal monitoring of single TDL is warranted.

Case 12

1. Approximately 3% to 5%.
2. Young age, the presence of additional lesions separate from the mass, and neurologic symptoms spaced over time and location favor demyelinating disease.
3. Approximately 10%.
4. Elevated oligoclonal bands (90% of cases) and elevated IgG (approximately 75% of patients).

Comment

Although the etiology of multiple sclerosis is unknown, several causative factors have been implicated. These include autoimmune disease, infection (viral agent), and genetic factors. The prevalence of multiple sclerosis varies with geographic location.

Variants of multiple sclerosis may be present on a clinical or imaging basis. A handful of rare borderline types of multiple sclerosis occur, including Marburg type (also known as acute, fulminant, or malignant multiple sclerosis), a form of acute multiple sclerosis usually seen in younger patients that may be preceded by fevers, is typically rapidly progressive, and can result in death. In such cases, there is extensive demyelination and there may be defined rings within or surrounding plaques of acute demyelination. Enhancement is typically seen in the region of these rings. Concentric sclerosis or Balotype sclerosis is characterized histologically by alternating rings of demyelination and myelination (normal brain or areas of remyelination) and has a characteristic MR imaging appearance. Schilder's disease is a rare progressive demyelinating disorder that usually begins in childhood. Symptoms may include dementia, aphasia, seizures, personality changes, tremors, balance instability, incontinence, muscle weakness, headache, and visual impairment.

A type of multiple sclerosis that is usually limited to the optic nerves and spinal cord (either simultaneously or separately) is Devic's disease or neuromyelitis optica. The main symptoms of Devic's disease are loss of vision and spinal cord dysfunction. The visual impairment can consist of reduced visual fields, diminished light sensitivity, or loss of color vision. Spinal cord dysfunction includes muscle weakness and lack of coordination, reduced sensation, and incontinence. The brain is usually spared.

“Tumefactive” multiple sclerosis on imaging may be mistaken for a neoplasm or occasionally an abscess, particularly in the absence of a clinical history. The age of the patient may be helpful (multiple sclerosis typically occurs in younger patients). In addition, on close questioning, patients often have neurologic symptoms that are spaced in both time and location. MR imaging may show white matter lesions separate from the mass, suggesting multiple sclerosis. Unlike neoplasms, tumefactive multiple sclerosis often has relatively little mass effect for the amount of signal abnormality present.

Case 13

1. There is a confluent, symmetric white matter abnormality that begins in the frontal lobes and progresses posteriorly. There is usually relative sparing of the subcortical U-fibers and the white matter within the basal ganglia.
2. Active demyelination and perivascular inflammation.
3. X-linked or autosomal recessive.
4. Canavan disease.
5. Krabbe disease, metachromatic leukodystrophy (MLD), Alexander disease, Canavan disease.

Comment

Adrenoleukodystrophy is an X-linked or autosomal recessive disorder that is related to a single enzyme deficiency (acyl coenzyme A synthetase) within intracellular peroxisomes. This enzyme is necessary for β oxidation in the breakdown of very long-chain fatty acids that accumulate in erythrocytes, plasma, and fibroblasts, as well as the CNS white matter and adrenal cortex. Boys typically present between the ages of 4 and 10 years. The clinical presentation may include behavioral disturbance, visual symptoms, hearing loss, seizures, and eventually spastic quadriparesis. Patients often present with adrenal insufficiency (Addison’s disease), which may occur before or after the development of neurologic symptoms.

As in other demyelinating and dysmyelinating disorders, MR is the imaging modality of choice for the detection of white matter disease, being far superior to CT. In adrenoleukodystrophy, the most common pattern of white matter disease is bilaterally symmetric abnormalities within the parietal and occipital white matter, extending across the splenium of the corpus callosum. The disease may continue to progress anteriorly to involve the frontal and temporal lobes. The region of active demyelination, usually along the anterior margin, may

show contrast enhancement. Less typical presentations include predominantly frontal lobe involvement or holo-hemispheric involvement.

Adrenoleukodystrophy also involves the cerebellum, spinal cord, and peripheral nervous system.

Case 14

1. There is FLAIR high signal intensity and enhancement in the mamillary bodies as well as T2W and FLAIR high signal intensity in the medial thalami.
2. Wernicke encephalopathy.
3. Thiamine deficiency, usually in the setting of chronic alcoholism.
4. Venous ischemia or infarction (due to deep vein thrombosis) and infarct of the artery of Percheron (a single vascular pedicle that supplies the paramedian thalamic arteries).

Comment

This case shows many of the radiologic findings seen in Wernicke encephalopathy. FLAIR shows high signal intensity and enhancement in the mamillary bodies and FLAIR high signal intensity in the medial thalami. Wernicke encephalopathy is typically associated with generalized cerebral cortical and cerebellar vermal atrophy. In addition, specific deep structures are involved and are best assessed with MR imaging, which is more sensitive than CT in evaluating the small structures involved in this entity. Abnormal T2W and FLAIR hyperintensity is seen in the mamillary bodies (in essentially all patients), and may also be seen in the hypothalamus, periaqueductal gray matter, and medial thalami.

Imaging findings are often bilaterally symmetric. In the acute setting, there may be mild swelling associated with the signal alteration, and enhancement was also been reported. Resolution of the signal alterations after treatment with thiamine has been reported. In the late stages, atrophy (particularly of the mammillary bodies) may be the main finding.

Wernicke encephalopathy is related to thiamine deficiency and is found most commonly in chronic alcoholism; however, this vitamin deficiency may also be present in other conditions that result in chronic malnutrition, such as anorexia nervosa, prolonged infectious or febrile conditions, and hyperemesis gravidarum. Wernicke syndrome has also been reported in association with long-term parenteral therapy. In contrast, Korsakoff psychosis is manifested by

retrograde amnesia and difficulty acquiring new information. The two sometimes occur together.

Case 15

1. (A, B) Axial DWI and corresponding ADC map through the lateral ventricles. There is bilateral perisylvian restricted diffusion. The right basal ganglia is involved, while the left posterior lentiform nucleus and the adjacent left coronal radiata are involved as well. Inferior extension into the anterior temporal lobes (not shown) was present bilaterally.

(C, D) 3D time of flight MRA of the head obtained on day 1 showing nonvisualization of bilateral internal carotid arteries and the left middle cerebral artery (MCA). The right MCA (vertical arrow) is attenuated. Its occlusion is probably responsible for the new infarct on the right side. Bilateral anterior cerebral arteries (ACAs) (transverse arrows) show robust intensity.

2. N/A.

3. Bilateral MCA territory acute infarction.

4. A patent circle of Willis (COW) ensures adequate compensation for occlusions. The posterior communicating arteries are present, thus routing blood from the posterior circulation to the ACA via the supraclinoid ICA. Anastomosis of the ECA and ICA via the ophthalmica artery is another route of blood from the extracranial circulation to the intracranial circulation. Other collateral circulations include the posterior/anterior pericallosal arteries around the splenium of CC and leptomeningeal collaterals not necessarily visualized in this case. Contrast-enhanced MRA or CTA may be useful in demonstrating these collaterals.

5.

- Size and location of infarcts
- Complications such as mass effect, herniations, hydrocephalus, hemorrhage
- Complete MRA or CTA of the head and neck is necessary for evaluation of vascular structures

Comment

The classical MRI finding of acute/subacute ischemic infarct is the restricted diffusion—hyperintense on DWI with low ADC. This becomes evident

within the first 30 minutes before the FLAIR and T2WI changes are clearly visible. It may take up to 2 hours for FLAIR and T2WI changes to be seen. The initial mass effect is local. Simultaneous acute bilateral MCA territorial infarcts are unusual. CT may show hypodensity in the same locations. The MCA is the largest vascular territory in the brain and the most common location for infarcts. Embolic phenomenon tends to be common in the MCA territory since it receives a disproportionate share of the blood.

Atherothrombotic changes and in this situation Internal carotid artery (ICA) occlusion are not uncommon. There is a necessity to evaluate the neck vasculature either by CTA or by contrast MRA in this patient in order to prescribe appropriate management. Large MCA infarction has been found to be associated with cardiogenic embolism, ICA occlusion, and ICA dissection. Subsequent CTA of the neck revealed an occluded left ICA at origin with a (presumably recanalized) 95% stenosis of the right ICA origin. There appear to be significant collaterals to the MCA territory since only the perisylvian territories are affected despite occlusion of M1 on the left and significant disease on the right.

MCA infarcts present with aphasia, hemiparesis, mental status changes, and coma. The prognosis of a complete MCA territory stroke is very poor. Life threatening MCA infarction, so called malignant MCA stroke, occurs in up to 10% of all stroke patients with the main cause of death being severe edema leading to raised intracranial pressure, clinical deterioration, coma, and death. Brain swelling with mass effect develops rapidly and appears to peak within 5 days of the ictus. Uncal, subfalcine, and transtentorial herniations and hemorrhagic transformations are not uncommon complications. Large MCA infarction is a major predictor of death and severe disability.

Case 16

D. Right parietal lobe.

This is the classical history of someone with a nondominant (right) parietal lobe lesion causing “neglect”; the patient may eagerly hunt for the examiner’s face on the right when the voice is called from the left, and the patient may deny that the left side of the body exists (even a dense hemiparesis may be cheerfully “overlooked”), or the patient may fail to acknowledge as one’s own the left arm held up in plane view by the examiner.

Case 17

1. (A) Axial T1WI through the basal ganglia. There is symmetrical hyperintensity in the globi pallidus (arrows). (B) Axial T2WI through the centrum semiovale. There are patchy and nonspecific white matter abnormalities in both hemispheres (arrows). (C) Short TE (31 ms) proton MR spectra show elevation of glutamine and glutamate (arrow).
2. Hypoxic-ischemic encephalopathy, neurofibromatosis type 1, Japanese encephalitis, hyperalimentation or total parenteral nutrition (manganese deposition), hemorrhage (methemoglobin), Wilson disease (copper toxicity and subsequent gliosis), basal ganglia calcification, nonketotic hyperglycemia associated with choreaballism, hypothyroidism, and carbon monoxide intoxication.
3. Chronic hepatic encephalopathy (HE).
4. Manganese-related MR signal abnormalities have also been described in patients receiving total parenteral nutrition, patients with occupational exposure to manganese from welding, and patients with noncirrhotic portal vein thrombosis or congenital portal-systemic bypass without intrinsic hepatocellular disease.
5. The signal changes in T2WIs are increasingly reported as attributable to brain edema and reside in astrocytes but may also be located in the interstitial compartment or be secondary to disturbances in the blood–brain barrier causing mild brain edema in cirrhotic patients.
6. Exclude intracranial hypertension, acute hemorrhages, or space-occupying lesions.

Comment

MRI is the examination of choice in the evaluation of the patient with HE. CT may show nonspecific findings. Hyperintense signal on T1WI in the basal ganglia (predominantly globus pallidus [GP]) and midbrain and hyperintense signal in T2WI in thalami, posterior limb of the internal capsule, and periventricular white matter that may also extend to the subcortical white matter and perirolandic regions are the hallmarks of HE. Proton MR spectroscopy may show elevated glutamine-glutamate and a decrease of choline and myoinositol.

These changes are interpreted as compensatory response to the increase in intracellular osmolality caused by the accumulation of glutamine in astrocytes. The T1 signal abnormalities commonly resolve within a year following liver transplantation, and there is also a reduction in T2 signal abnormalities in the hemispheric white matter or around the corticospinal tracts after liver transplantation, suggestive of brain edema not only in the acute setting but also in chronic HE. Apart from hyperalimentation, methemoglobin, and some forms of calcification, bilateral symmetrical T1-weighted hyperintensity in the GP is not present in any of the differentials.

The pathophysiologic mechanisms of HE are not definitively established, but liver dysfunction disables detoxification of portal venous blood so that toxic substances accumulate and enter into the bloodstream (via a portosystemic shunt) causing potential damage to the central nervous system. Manganese is one of these toxic substances that shows preference to accumulate in the basal ganglia, predominantly in the GP, and is revealed by MRI signal changes described earlier. These changes reflect hyperammonemia which causes a rise in brain glutamine in astrocytes and increased intracellular osmolality which are responsible for profound astrocyte changes including Alzheimer type II changes seen commonly in chronic HE and astrocyte swelling in acute HE. These abnormalities induce compensatory metabolic changes as brain edema, from mild to severe edema and intracranial hypertension (as in fulminant hepatic failure).

HE is a clinical neuropsychiatric syndrome that occurs in patients with liver dysfunction, in the setting of either acute liver failure or acute superimposed on chronic or chronic liver disease. The manifestations of HE vary from mild alterations of mental status to severe coma and are sometimes associated with motor function changes and cerebellar signs (these are mainly in chronic stages), depending on the liver disease clinical stage as designated by the West Haven classification.

References

1. N. D. Kitchen, H. Manji, G.M. McKhann II. Self-Assessment Colour Review of Clinical Neurology and Neurosurgery, Manson Publishing Ltd, London, UK, 2003.
2. T.G. Psarros, S.P. Moore. Intensive Neurosurgery Board Review. Lippincott Williams&Wilkins, Philadelphia, 2006.
3. R. Nader, A.J. Sabbagh. Neurosurgery Case Review. Questions and Answers. Thieme Medical Publishers, Inc., New York, Stuttgart, 2010.
4. M.F. Omojola, M. Castillo. Neuroimaging: A Teaching File. Wolters Kluwer Health, Philadelphia, 2015.
5. Laurie A. Loevner. Brain imaging: Case Review, 2nd Ed., Mosby Elsevier, Philadelphia, 2009.
6. S.T Pendlebury, P.Anslow, P.M Rothwell. Neurological Case Histories. Oxford University Press, New York, 2007.