

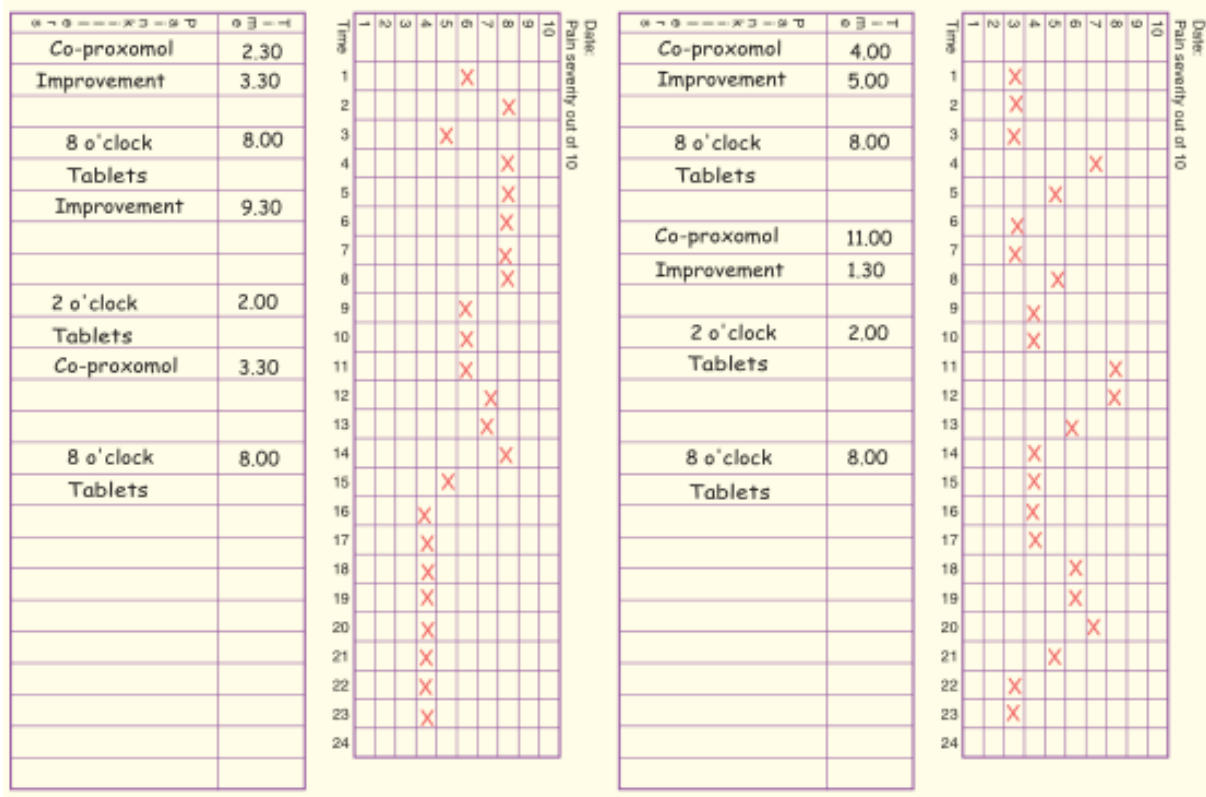
## EANS/UEMS European examination in neurosurgery

Variants of questions with answers (compilation - Vyacheslav S. Botev,  
Department of Neurosurgery, M.Gorky Donetsk National Medical University)

### CASE HISTORIES IN FUNCTIONAL NEUROSURGERY

#### Case 1

This is a headache diary of a patient who gives a history of this pattern of head pain, daily over the last 5 years.



#### Questions

1. What is the most likely diagnosis?
2. What does the diary show?
3. What is the most important part of the management of this patient?

## Case 2

A 58-year-old male with no significant past medical history has come to see surgical treatment for his medically refractory TGN. He wishes to undergo a surgical procedure that has the highest success rate, and the longest pain-free interval available. After elaborating on the associated surgical risks of the plethora of available procedures, the patient is adamant in receiving the most effective and long-lasting treatment. Which procedure would you recommend?

## Case 3

A 22-year-old college student was an unrestrained passenger involved in a motor vehicle accident. She was quadriplegic on the scene, but able to breathe without mechanical assistance. Neuroradiologic imaging studies revealed a contusion of the cervico-thoracic cord but no mechanical instability. Over the next few weeks of intensive rehabilitation therapy, the patient slowly regained most of her sensorimotor functions in all four extremities, but a moderate pain/temperature sensory loss persisted. Approximately 7 months following the accident, the patient began to suffer from progressive burning and searing pain in all four extremities with a quality and severity she had never experienced. In addition, she noted increasing weakness in her upper extremities.

### Questions

1. What would be the next most ideal treatment/diagnostic option?
2. What are some of the surgical options that may be beneficial in **alleviating** the patient's symptoms?

## Case 4

A 16-year-old boy with cerebral palsy and a long history of seizures is referred to you for a vagal nerve stimulator (VNS) placement. The mother wishes the generator to be placed on the right side because of flexion contractures in the left upper extremity.

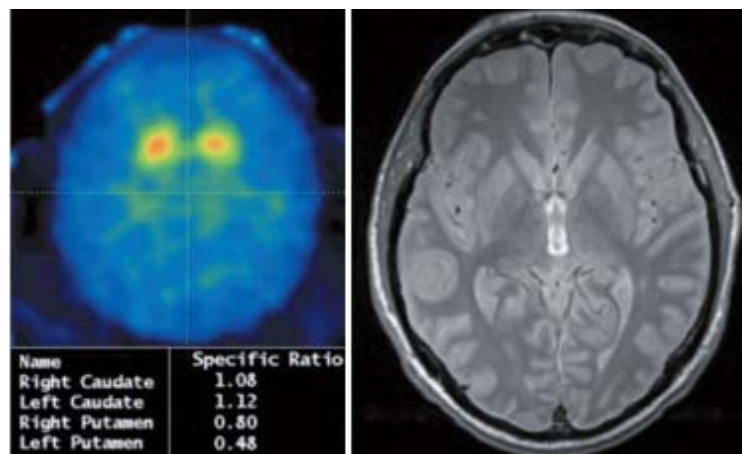
### Questions

1. What is the mechanism of action of VNS?
2. How do you identify the vagal nerve in the neck for implantation?

3. Where on the vagal nerve should the lead wires be ideally placed and is there any concern regarding VNS placement on the right side?
4. What are the reported results for VNS use in epilepsy?
5. What are the usual initial VNS settings for use?
6. What are the usual side effects of VNS placement?
7. The patient returns to you a month later with pus draining out from the battery site. What are your options?
8. Antibiotics and your debridement cleared the infection. What are you going to do next?
9. A few weeks after reimplantation of the battery at the new site, the patient presents with infection along the leads extending into the neck. What are your options now?
10. Nine months after all the infection is cleared, the patient is referred to you once more for reimplantation of VNS. What are your options now?
11. Other than the treatment of seizures, is there an other indication for VNS placement?

### Case 5

A 67-year-old male noted to have gradually increased frequency of falling, right hand tremor particularly when he is walking, smaller handwriting, trouble opening boxes and caps, softer voice, decreased facial expression, depression, neck stiffness, stooped posture and shortened strides, and executive dysfunction.



1. Describe the findings on the imaging study.
2. What is the differential diagnosis?
3. What is your diagnosis?
4. What is the best follow-up imaging modality?
5. What the treating physician needs to know?

## Case 6

Drug-induced Parkinsonism.

A 71-year-old Mr Roach was admitted to the acute medical unit yesterday following a fall. The admitting doctor noted he has a symmetrical tremor. He has been reviewed on the post-take ward round, and a series of investigations to identify the cause for his fall have been requested.

PMH Schizophrenia. At his last psychiatric outpatient review 3 months ago his psychotic symptoms were noted to be well controlled with quetiapine; on review of side effects he complained of nausea and occasional vomiting, so metoclopramide was started.

DH Quetiapine 150 mg 12-hourly, which he has been taking for the past 5 years. Metoclopramide 10 mg 8-hourly for the past 3 months.

On examination, he has a mild chin tremor and a symmetrical resting tremor affecting his hands with some cogwheeling. There is no discernible bradykinesia. He has a normal gait and postural reflexes, and motor, sensory and cerebellar examinations are otherwise normal.

Task

Your consultant has reviewed Mr Roach on her post-take ward round. She has asked you to review his medications to look for a drug cause for his tremor and modify his treatment if appropriate.

1. Which common drug causes of Parkinsonism?
2. What action should I take?
3. How do I write the prescription?

## Case 7

Tic Douloureux

An 83-year-old right-handed man presents with a 2-year history of neuralgia-like pain on the right side of his face involving the ophthalmic (V1) and maxillary (V2) divisions of the trigeminal nerve. He has been taking carbamazepine and topiramate, which provided minimal relief, and says he no longer wishes to use these medications.

The patient underwent a microvascular decompression (MVD) procedure. At the time of surgery, the trigeminal nerve was found to be in severe compression by a

redundant vertebrobasilar complex ventrally and inferiorly and by the anterior inferior cerebellar artery superiorly. Decompression was achieved using small pieces of Teflon paddies. He experienced immediate and complete recovery of his pain following surgery.

## Questions

1. What are the different types of facial pain syndromes?
2. What are the characteristics of the pain in trigeminal neuralgia?
3. What are the main nuclei of the trigeminal nerve, and what functions do they serve?
4. What is the initial management of a patient with trigeminal neuralgia?
5. What are the surgical indications?
6. What are the other treatment options?
7. Which vessel is the most common culprit of the compression?
8. What are the efficacies of MVD and other treatment options in trigeminal neuralgia?

## Case 8

### Hemifacial Spasm and Microvascular Decompression

A 35-year-old man presents with a 10-year history of spasmodic twitching on the left side of his face. The twitching involves the left eyelid and causes intermittent spasmodic closure of the eye. The attacks of hemifacial spasm (HFS) are exacerbated by stress.

## Questions

1. What is the most likely diagnosis? The differential diagnosis?
2. Describe the pathophysiologic basis of HFS.
3. What is the underlying cause of HFS?
4. What are the surgical and nonsurgical therapeutic options?
5. Briefly describe your surgical procedure for HFS.
6. What is the expected surgical outcome?
7. What are the possible surgical complications?

## Case 9

### Complex Regional Pain Syndrome

A 47-year-old woman is walking from one commuter train car to the next, when the sliding door closes on her right arm and shoulder, trapping her for 3 to 4 minutes; during this time, she begins to experience stabbing pain throughout her right arm. She extricates herself, and later that day is evaluated in the ED, where no discernible injuries or neurologic deficits are discovered. Because her pain persists weeks after her injury, she undergoes magnetic resonance imaging of her cervical spine, which only shows some mild, nonspecific degenerative changes. She was treated with nonsteroidal antiinflammatory drugs and short-acting opiates, which offered partial relief of her pain.

#### Questions

1. Based on the available information, what is the differential diagnosis for this patient's pain?

2. What studies do you order?

Her electrodiagnostic studies were normal. On repeat examination a few months after injury, the patient was developed right upper extremity swelling from the shoulder to the forearm, and the entire arm is painful to touch and also to either active or passive movement.

3. What is the most likely diagnosis at this point?

4. Describe the initial, noninvasive treatment of this condition.

5. Describe the invasive treatments of this condition, for use when conservative measures fail.

The patient undergoes a comprehensive, multidisciplinary approach to treat her condition. Although she is able to tolerate physical therapy, her arm still greatly bothers her; she still has swelling and stiffness in the arm, and she cannot work. She has tried several medication trials without sufficient pain relief, and several anesthetic blocks were unhelpful. A psychological evaluation was unrevealing.

6. You now wish to employ spinal cord stimulation (SCS).

Where will you place the electrodes?

7. What are the potential complications of SCS?

8. What are the outcomes for spinal cord stimulation in patients with complex regional pain syndrome (CRPS)?

## Case 10

Which animal is associated with a headache that characteristically occurs in the morning?



- A. Skunk
- B. Turtle
- C. Giraffe
- D. Possum
- E. Armadillo

## Case 11

Spasticity after Cord Injury

A 64-year-old man presents 6 years after having sustained a motor vehicle accident. The patient is a recovered C4 partial quadriplegic who underwent a C4 corpectomy and C5–6 anterior cervical discectomy and fusion about one year ago. He now presents with some upper extremity pain and bilateral shoulder pain. He has some persistent spasticity in both upper and lower extremities, unsteady gait, and difficulties with bladder control. Hyperreflexia and muscle atrophy are seen diffusely on examination. He has been taking baclofen, tramadol, and diazepam, but the effect of the medications seems to have worn off despite a recent increase in dosage. Magnetic resonance imaging (MRI) of the

entire spine is done, a small syrinx is seen at the level of C4–5, but it is not causing any pressure on the cord or any compression of neural elements.

## Questions

1. How do you manage the syrinx?
2. What are some other causes of spasticity?
3. Describe a grading system for spasticity.
4. What are some other medical options to treat spasticity in this patient?
5. Name five surgical options commonly employed to treat spasticity.
6. What are the main complications of pump placements?
7. What are the main selection criteria for placement of baclofen pumps?

## Case 12

A 74-year-old man with progressive inability to walk over the past year comes to your office. He said: “My walking is getting really slow”. He also has a hard time getting up from a seated position and he becomes lightheaded when he tries.

On examination, he is immobile, seems very “grim-faced”. Tremor at rest at 3 cycles/second, cogwheeling present. Slow gait, significant retropulsion. He cannot easily turn.

The patient’s diagnosis of Parkinson disease (PD) is obvious on examination. There is no test to specifically diagnose PD. An MRI of the head can be used to see if there are previous strokes that led to the PD. All of your examination questions on PD will concern drug therapy, and the basic science fundamental questions will be on the mechanism of these treatments.

1. Which should be tested for on examination?
  - A. Hyperreflexia
  - B. Orthostatic hypotension
  - C. Spasticity of muscles
  - D. Decreased papillary reflexes

You start treatment with anticholinergic agent benztropine. Instead of the previously scheduled 2-week follow-up appointment, the patient is brought back in 4 days by his wife. He has abdominal pain, dry mouth, and urine retention.



2. Which of the following should you also ask about or examine for?

- A. Bradycardia
- B. Memory difficulty
- C. Diarrhea
- D. Constricted pupils

You stop the benzotropine and start amantadine. When you see the patient again in 2 weeks, there is no significant improvement.

3. What is the next step to try?

- A. Catechol-O-methyltransferase (COMT) inhibitor (tolcapone, entacapone)
- B. Ropinirole or pramipexole
- C. Bromocriptine
- D. Selegiline

4. What is the mechanism of carbidopa?

- A. Direct dopamine agonist
- B. Inhibition of dopamine decarboxylase
- C. Decreased urinary excretion of dopamine
- D. Synergistic with dopamine at substantia nigra

5. What should you do?

- A. Nothing more can be done
- B. Add tolcapone or entacapone
- C. Order deep brain stimulation

6. What is the mechanism of the hallucinations?

- A. It is the direct toxicity of the COMT inhibitor
- B. The patient has decreased serotonin levels
- C. Dopamine increases psychosis
- D. Decreased ACh increases psychosis

### Case 13

The patient is a 55-year-old man in good health until about 6 months ago. At that time he noticed development of a tremor. On examination, there is a tremor in the right arm at rest and while he walks, he has a sustained tremor in both arms, and to some degree during finger-nosefinger maneuver (fairly fine and without an obvious rhythm). He has a poker face and a slow, deliberate gait.

Tone is increased in the right arm and leg. He deny use of alcohol or any other medications.

1. What is the most likely diagnosis?
2. What is the next diagnostic step?
3. What is the next step in therapy?

#### **Case 14**

A 66-year-old retired policeman presents with few months history of abnormal shaking movements involving his arms and head. He said that these movements become less upon drinking alcohol. Examination revealed symmetrical fine tremor of both hands with prominent postural component, somewhat regular head shaking movements but no jaw tremor. What is your next step?

- A. Brain CT scan with contrast
- B. 24 hours urinary copper measurement
- C. T3, T4, and TSH blood level
- D. No investigation is needed to confirm the diagnosis
- E. EMG and nerve conduction studies

## Answers

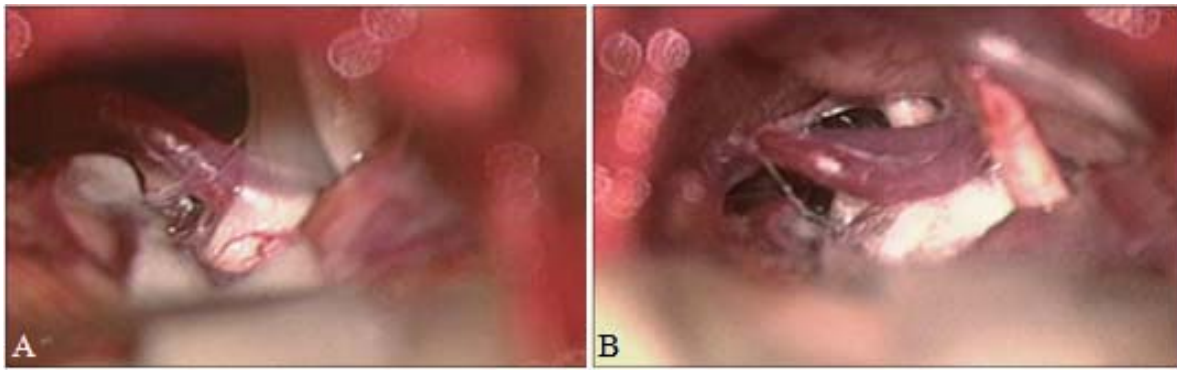
### Case 1

1. This patient has chronic daily headache with analgesic overuse.
2. The diary shows typical analgesic rebound headaches, improved each time with further analgesic intake.
3. The most important part of the management is to withdraw the analgesics. The current operational definition of daily headache is >15 days of headache each month. Population based 1-year prevalence rates of chronic daily headache are about 4%. At least half of these patients are overusing acute-relief medications. The majority of patients presenting to neurology clinics with chronic daily headache are overusing acute-relief medications. Most give a pre-existing history of a primary headache syndrome, most commonly migraine. The mean duration of primary headache is 20 years, the mean time of admitted frequent medication use at least every second day is 10 years and the mean duration of daily headache is 6 years. It seems that the frequency of acute-relief medication use is more important rather than total consumption. Ergotamine, caffeine, the 'triptans' and almost all types of analgesics alone have been implicated. The latter group includes codeine, paracetamol and aspirin.

Withdrawal of acute-relief medication results in improvement in many but not all patients. The average 'analgesic washout period' before significant improvement is observed is about 3 months. Once acute-relief medication has been withdrawn, prophylactic agents are more effective. Management of these patients should be aimed at minimizing the use of abortive treatment and introducing suitable prophylactic therapy.

### Case 2

The most effective and longest lasting surgical technique for TGN is microvascular decompression, refined and popularized by Peter Jannetta. The procedure is based on the concept that compression of the fifth cranial nerve at the root entry zone by nearby vasculature causes demyelination leading to abnormal electrical conduction and resultant pain. The most frequent vessel causing compression is the SCA (80%), followed by the AICA and basilar artery (A).



After performing a suboccipital craniectomy, suspect vessels are mobilized and a small piece of inert material, such as a Teflon pledget, is interposed to prevent compression (B).

It is a major neurosurgical procedure but carries <1% mortality, and 3% persistent major morbidity, in experienced hands. Morbidities include intracranial hemorrhage, transient hearing loss, and minor sensory loss. With over an 8-year follow-up period, 60% of patients are pain free and 70% have good pain relief, despite greater than 90% initial pain relief. Microvascular decompression, while associated with a higher mortality and morbidity rate, provides excellent long-lasting pain relief in medically-fit patients suffering from classical TGN. An appealing and viable alternative is gamma knife radiosurgery which provides good to excellent pain relief in 75% of patients, with 75% of responders experiencing good pain relief for a median interval of 18 months.

### Case 3

1. Pain occurs in approximately 50% of patients with spinal cord injury. In a patient with new and progressive neurologic findings, however, one must always be vigilant for the development of syringomyelia.

The next most appropriate diagnostic test in this patient would therefore consist of a cervicothoracic MR scan which may demonstrate a syrinx within the spinal cord, and a normally appearing nerve root. In patients with stabilization hardware (common after severe spinal column injury) preventing MR imaging, a delayed myelogram CT scan may reveal dilatation of the spinal cord, and/or collection of contrast material within the cord.

2. Pain improves in a majority of patients after undergoing shunting of the syrxinx, usually via the placement of a syringo-subarachnoid shunt. Additional treatment modalities, including DREZ lesions and medial/ventrolateral thalamic lesions/stimulation, have provided varying degrees of pain relief.

#### Case 4

1.

- The precise mechanism of action of VNS is unknown.
- It has been suggested that VNS has action on various regions of the brain including the locus ceruleus, amygdala, hippocampus, and contralateral somatosensory cortex.
- Another proposed mechanism of action is the possibility that VNS increases  $\gamma$ -aminobutyric acid (GABA) and glycine levels in the brain.
- Ben-Menachem et al. measured amino acid and neurotransmitter metabolite concentrations in cerebrospinal fluid (CSF) samples of patients on clinical trials of VNS before and 3 months after VNS placement.
- Their results showed an increase in GABA level among patients that failed to respond to VNS stimulation, those with a lower setting of stimulation, as well as patients who had undergone a long-term VNS stimulation.
- Yet others have indicated that VNS decreases cortical epileptiform activity directly and possibly also affects blood flow through different regions of the brain.

2.

- The vagal nerve is in the posterior part of carotid sheath between the carotid artery and internal jugular vein.
- Caution is advised to differentiate the vagus from the phrenic nerve, which traverses in the anterior part of the sheath.

3.

- The right vagal nerve innervates the sinoatrial (SA) node more than 60%, whereas the left vagal nerve mostly innervates the atrioventricular (AV) node of the heart.
- Placement of the leads on the right vagal nerve is contraindicated, as the stimulation will result in asystole.
- The risk of bradycardia exists even when the electrodes are placed on the left vagal nerve.
- What the mother wished was for the battery pocket to be placed on the right

side secondary to flexion contractures of the left upper extremity. This can be done and should be considered given the contractures.

- The ideal place for implantation of leads on vagus is in the middle part of the neck proximal to the branches to the cardiac plexus.
- The three lead wires are placed from proximal to distal along the nerve.

#### 4.

- In the Vagus Nerve Stimulation Study Group E05 trial, the median reduction in seizure frequency at 12 months after completion of the initial doubleblind study was 45%.
- Overall, 35% of the patients had a reduction in seizures of at least 50%; 20% of the patients demonstrated a 75% reduction in their seizure frequency.
- Similar results have also been reported in the XE5 trial.
- A 12-year retrospective review of the effectiveness of VNS in 48 patients with intractable partial epilepsy reported a mean decrease in seizures frequency by 26% after 1 year, 30% after 5 years, and 52% after 12 years.

#### 5.

- Although some centers initiate stimulation the days after implantation, usually the generator is kept turned off and an increase in output is advanced by the neurologists after a 2-week postoperative period.
- Typically, the output is adjusted to tolerance, using a 30-Hz signal frequency, with a 500-microsecond pulse width for 30 seconds of “on” time and 5 minutes of “off” time.
- This is not standard and multiple variations exist depending on the clinical situation.

#### 6.

- The most common side effects of VNS are cough, hoarseness, and throat pain.
- Unlike antiepileptic drugs, VNS has not been associated with adverse effects such as depression, fatigue, confusion or cognitive impairment, etc.

#### 7.

- Infection at the site of battery would necessitate removal of the battery and treatment with debridement and antibiotics.
- The lead wire could be left in place and moved away from the infected site.

8. Once the infection is cleared, a new battery should be implanted at another site in the anterior chest wall and reconnected to the lead wires.

#### 9.

- If there is suspicion of infection along the lead wires, then the neck incision should be opened and explored.
- The wires should be cut close to the vagus nerve's lead implantation site and the leads should be left in situ.
- Attempting to remove the leads from the vagus nerve will result in injury to the nerve.

10. The vagus nerve can be explored proximally in the neck and if it is possible to implant another set of leads on the vagus nerve, it should be done proximal to its cardiac branches.

11. Other indications for use of VNS include refractory depression, and research is being conducted for its use in the treatment of such varied diseases as anxiety disorders, Alzheimer disease, migraines, and fibromyalgia.

## Case 5

1. This is an abnormal  $^{123}\text{I}$ -FP-CIT (DAT scan) SPECT. There is symmetrical decrease of tracer uptake in the bilateral putamen indicating loss of dopamine transporters (DATs) compatible with the diagnosis of Parkinson disease (PD). Axial T2 MRI through the basal ganglia. There are no structural abnormalities in the bilateral basal ganglia.

2. Normal pressure hydrocephalus (NPH), Parkinson-plus syndromes (progressive supranuclear palsy, multisystem atrophy, corticobasal degeneration), dementia with Lewy bodies, Alzheimer disease.

3. PD with early cognitive impairment.

4. SPECT with DAT radioligands is promising to shown dopamine producing nigrostriatal neuron reserves.

5. Despite the diverse clinical presentation, differentiation of PD from NPH can be challenging. Moreover, NPH is a treatable condition, whereas PD treatment options are only symptomatic and imaging features may overlap

## Comment

Imaging is supportive or exclusionary in cases of atypical presentations of PD. Positron emission tomography (PET) with the florodopa ligand and single photon emission computed tomography (SPECT) are the principal options. MRI is nonspecific showing loss of structural integrity of substantia nigra pars compacta on T2-weighted scans. In SPECT studies, DAT radioligands are used to determine the presynaptic integrity of dopamine producing nigrostriatal neurons. The classic picture is usually asymmetric, reduced radiotracer uptake in the striatum bilaterally, particularly affecting the posterior putamen.

Continuation of dopamine therapy is not a contraindication for SPECT. Of note, when SPECT does not imply dopaminergic dysfunction, the clinical diagnosis of PD is likely false positive, and the true diagnosis may be a variant of essential, dystonic, or drug-induced tremor and dopa-responsive dystonia with parkinsonism. On the other hand, SPECT has no role in differentiating atypical parkinsonism from PD, as all shown dopaminergic dysfunction.

PD is the second most common neurodegenerative disorder after Alzheimer disease. The majority of cases are idiopathic. The clinical presentation is a combination of rest tremor, rigidity, postural instability, and bradykinesia. Pathologically there is accumulation of Lewy bodies, cytoplasmic (alpha)-synuclein inclusion in surviving neurons in the substantia nigra pars compacta. Neuronal degeneration precedes the clinical presentation. Unfortunately, motor symptoms are elicited after loss of about 60% of the dopaminergic substantia nigra neurons. This translates into 80% less than normal dopamine content in the striatum. There is additional involvement of nondopaminergic cholinergic neurons in the nucleus basalis of Meynert, noradrenergic neurons in the locus coeruleus, and serotonergic neurons in the midline raphe responsible for nonmotor symptoms such as cognition, mood, autonomic function, and the sleep cycle.

There is no cure or well-established disease-modifying therapies; symptomatic relief with levodopa is the most commonly used therapy. However, besides the inherent motor symptoms of PD, long-term exposure to levodopa itself has motor complications. Indeed, deep brain stimulation has replaced ablative procedures used in motor complications and the management of treatment refractory tremor.

Targets for deep brain stimulation procedures are subthalamic nucleus (STN) stimulation, thalamic stimulation, and pallidal stimulation. MRI is the best choice of modality for surgical assistance.



## Case 6

Drug-induced Parkinsonism is an example of a ‘continued use’ adverse drug reaction: where prolonged use over weeks to months (i.e. the cumulative dose) leads to an adverse effect. Drugs are a common cause of secondary Parkinsonism. Features to suggest drug-induced Parkinsonism include symptoms that relate to the timing of drug administration, symmetrical tremor (as opposed to unilateral) and associated abnormal oral–buccal movements. Patients particularly at risk include the elderly and women. Once the offending drug has been stopped, symptoms tend to fade over a period of months depending on the length of treatment, although some patients may require treatment with anti-muscarinic drugs or even levodopa or a dopamine agonist.

1. Common drug causes of Parkinsonism include drugs with central and peripheral anti-dopaminergic effects including first-generation anti-psychotic drugs (e.g., prochlorperazine, chlorpromazine and haloperidol) which block dopamine D2-receptors, anti-emetics (e.g. metoclopramide) and other drugs with non-dopaminergic effects such as anti-histamines (e.g. cinnarazine). The possible drug causes of Mr Roach’s Parkinsonism include metoclopramide and quetiapine. Metoclopramide is a dopamine D2-receptor antagonist, which is commonly used as an anti-emetic. Although the risk of extrapyramidal side effects such as tardive dyskinesia and Parkinsonism is rare, this risk increases with prolonged use. It is therefore recommended that long-term treatment (>3 months) is avoided where possible and patients are regularly reviewed.

Quetiapine is an atypical anti-psychotic with similar properties to clozapine. It antagonises various neurotransmitters in the brain, notably via the serotonin and dopamine D2 receptors. It is used in the management of schizophrenia, bipolar affective disorder and depression. In schizophrenia it has been shown to be effective at treating both ‘positive’ and ‘negative’ psychotic symptoms, and is at least as effective as typical anti-psychotics. Unlike most other anti-psychotics it has a low incidence of extrapyramidal side effects, similar to placebo. In fact, studies have demonstrated quetiapine to be a useful anti-psychotic agent in patients with Parkinson’s disease who have psychotic symptoms. However, although extrapyramidal side effects are less common with second-generation anti-psychotic drugs, they do still occur with appreciable frequency.

2. The first thing to do in Mr Roach’s case is to stop the metoclopramide and replace it with an anti-emetic that does not interfere with dopaminergic transmission.

Regarding the on-going use of quetiapine, your options are:

1. Continue quetiapine and wait to see if his symptoms subside after stopping metoclopramide
2. Continue quetiapine and consider adding an anticholinergic drug to control his tremor, or
3. Consider an alternative antipsychotic regimen, e.g. lower dose quetiapine, or switching to an alternative anti-psychotic such as clozapine.

The decision is a balance between minimising side effects while continuing to manage his schizophrenia. The simplest and probably best approach would be to stop the metoclopramide, continue quetiapine and wait to see if this leads to resolution of his tremor.

If the Parkinsonian symptoms do not resolve over the coming days to weeks, you may then need to reconsider whether it is appropriate to continue quetiapine. Adding in an anti-cholinergic drug to control his tremor is best avoided, as quetiapine has anti-cholinergic effects too, and it is good practice to avoid treating drug problems with more drugs where possible. Switching to an alternative agent would probably not be the best option in view of the fact that his schizophrenia appears to have been well controlled on quetiapine for the past 5 years. Any decision that could impact on the treatment of his schizophrenia should be guided by expert psychiatric advice.

### 3. Stopping medications.

Metoclopramide should be discontinued by crossing through the prescribing and signing and dating this. Be sure to record your assessment in the notes, making clear the reason for stopping metoclopramide, and add this to Mr Roach's list of intolerances.

Surname <b>ROACH</b>		Hospital number <b>100038</b>		Weight <b>68 kg</b>	Drug intolerances			
First name <b>JOSIAH</b>		Date of birth <b>06/06/1943</b>			None known Metoclopramide - Suspected drug-induced parkinsonism AD 7/1/15			
<b>REGULAR PRESCRIPTIONS</b>								
				Ords / vials times below ↓	In error dates below		Month: <b>January</b>	Year: <b>2015</b>
<b>QUETIAPINE</b>				6	7			
Dose <b>150 mg</b>	Route <b>Oral</b>	Freq <b>12-hrly</b>	Start date <b>6/1/15</b>	Ⓢ	Ⓢ			
Signature <b>A Doctor</b>		Block <b>1234</b>	Review	Ⓢ				
Additional instructions				Ⓢ				
				Ⓢ				

If he still has nausea, you should consider prescribing an alternative anti-emetic that does not act on dopamine receptors. A reasonable choice would be cyclizine. Existing medications. He should continue to take quetiapine while we wait to see if withdrawing metoclopramide improves his tremor.

AS REQUIRED MEDICATION										
DRUG <b>METOCLOPRAMIDE</b>				Date	6/1	6/1	7/1			
Dose	Route	Max freq	Start date	Time	1600	2200	0800			
10 mg	Oral	6-hrly	6/1/15	Dose	10mg	10mg	10mg			
Signature		Notes	Review	Route	Oral	Oral	Oral			
A Doctor		1234		Given	RP	RP	RP			
Additional instructions				Check						
Maximum 3 doses in 24 hours										
DRUG <b>CYCLIZINE</b>				Date						
Dose	Route	Max freq	Start date	Time						
50 mg	Oral	6-hrly	7/1/15	Dose						
Signature		Notes	Review	Route						
A Doctor		1234		Given						
Additional instructions				Check						
Maximum 3 doses in 24 hours										
DRUG				Date						

## Case 7

1. According to the classification proposed by Burchiel:

- Trigeminal neuralgia (type 1– predominant episodic and type 2 – predominant constant) or symptomatic trigeminal neuralgia (in multiple sclerosis)
- Trigeminal neuropathic pain
- Trigeminal deafferentation pain
- Postherpetic neuralgia
- Atypical facial pain

2. Characteristics of pain in trigeminal neuralgia:

- Sharp, shooting, electric shocklike pain
- Momentary or lasting only a few seconds
- Very intense
- Common provoking factors include touching, washing the face, teeth brushing, make-up, chewing, talking, eating, a cold breeze.
- May involve one or more branches of the trigeminal nerve

3.

- The principal sensory or main nucleus: Located in the upper pons, it conveys tactile and pressure senses from the face.
- The mesencephalic nucleus: Located near the central gray matter of the upper 4th ventricle, it conveys pressure and kinesthetic senses from the teeth, hard

palate, and jaw.

- The spinal trigeminal tract and nucleus: Extends from the upper cervical spine to the midpons, it is divided into three parts (pars caudalis, pars interpolaris, and pars oralis), which convey sensation of pain and temperature from different parts of the face.
- The motor nucleus relays fibers to the muscles of mastication and plays part in the jaw jerk reflex.
- The ventral and dorsal trigeminothalamic tracts relay sensory information to the ventroposterior medial nucleus of the thalamus.

4. Initial management in trigeminal neuralgia is medical. Medications that are most commonly used includes carbamazepine, gabapentin, lamotrigine, and Trileptal. Among these, carbamazepine is the most widely used. In addition, antidepressants or narcotic analgesics and steroids during severe pain episodes may provide temporary relief.

5. Indication for surgical treatment include failure of medical therapy, intolerance to the medications, and patients who do not like to take medications for a long time.

6. Other treatment options:

- MVD.
- Percutaneous techniques: glycerol rhizotomy (GR), balloon compression (BC), radiofrequency rhizotomy (RF).
- Gamma knife radiosurgery (GKRS).

7. Superior cerebellar artery (75%).

8. In a review by Taha and Tew, the initial pain relief was 98% in MVD and RF, 93% in BC, and 91% in GR. Ten years after surgery, excellent results were seen in 70% of cases who underwent MVD. Pain recurrence was seen in 15% of MVD, 21% in BC, 23% in RF, and 54% in GR.

Postoperative facial numbness and corneal anesthesia incidences were 2% and none in MVD, 60% and 4% in GR, 72% and 2% in BC, 98% and 7% in RF, respectively.

Therefore, when V1 or multiple divisions including V1 are involved, MVD is the preferred option to minimize the risk of corneal anesthesia. GKRS has been reported to be effective in 50–80% of the patients, with ~25% pain recurrence.

- The risk of facial numbness and dysesthesias increase with higher radiation dose in this technique.

## Case 8

1. The most likely diagnosis is HFS. Typical hemifacial spasm symptoms begin within the orbicularis oculi muscles and progress caudally. In atypical HFS, symptoms begin within the buccal muscles and progress rostrally.

Differential diagnosis:

- Benign essential blepharospasm
- Craniofacial tremor
- Facial chorea
- Tics
- Facial myokymia.

2.

- HFS is a neuromuscular disorder that is characterized by paroxysmal bursts of involuntary, intermittent, or continuous clonic movements that progress to sustained tonic activity occurring in the muscles innervated by the facial nerve.
- HFS represents a segmental myoclonus of muscles innervated by the facial nerve.
- Irritation of the facial nerve nucleus is believed to lead to hyperexcitability of the facial nerve nucleus, whereas irritation of the proximal nerve segment may cause ephaptic transmission within the facial nerve.
- Either mechanism explains the rhythmic involuntary myoclonic contractions observed in HFS.
- The disorder presents usually unilaterally, although bilateral involvement may occur rarely in severe cases.
- Typically, hemifacial spasm results secondary to vascular cross-compression of the myelinated facial nerve at or proximal to the junctional area of central and peripheral myelin (the root exit zone) of the nerve

3.

- The actual cause of HFS is debatable.
- Most cases of HFS are caused by an ectatic blood vessel that irritates the facial nerve by compressing or forming a loop around the nerve at the nerve exit zone. The usual offending artery is the posterior inferior cerebellar artery complex, the anterior inferior cerebellar artery, or the vertebral artery.
- A minority of cases of HFS are caused by a venous compression.
- Rarely, the condition may be secondary to facial nerve injury, facial nerve compression by a CPA tumor, regeneration of the facial nerve following facial palsy, or it may be a result of a brainstem lesion such as a stroke or a multiple

sclerosis plaque.

4. In mild and early cases, twitching can be controlled by the use of some antiseizure medications or minor tranquilizers, such as carbamazepine, clonazepam, and diazepam. However, results are not always satisfactory and medications need to be taken on a long-term basis.

5.

- Botulinum toxin injection directly into the affected muscles can ablate the muscular spasm for several months, but its effect is temporary and the sensation of spasm often persists.
- The response to the latter two treatment modalities varies and their effects often attenuate over time, necessitating a surgical treatment.
- As for surgical management, the definitive procedure is a microvascular decompression. The offending blood vessel is mobilized from the nerve exit zone. This may be performed through microscopic, endoscopic, or a combined method. Use of endoscopic visualization can improve the overall outcome.

6.

- Positioning and opening
  - Lateral decubitus position
  - Retromastoid craniectomy (2.0–2.5 cm in diameter)
  - Dura is incised.
  - Cerebrospinal fluid is drained slowly, allowing the structures of the posterior fossa to fall away without retraction.
  - Lateral or inferolateral cerebellar exposure of the CPA
- Dissection and decompression
  - The acousticofacial bundle is identified.
  - The facial nerve may be stimulated for verification.
  - The offending vessel is identified, and using microdissection and gentle manipulation, the adhesions and compressions from the vessel(s) on the facial nerve are lysed, and the nerve and vessel(s) are freed from one another.
  - Small implants of shredded Teflon felt are placed to hold the vessel away from the cranial nerve root exit zone by changing the axis of the loop. Other techniques may include performing a dural sleeve to hold the artery away from the nerve or gluing the artery to the posterior fossa dura.
  - Veins are treated similarly or coagulated and divided.

7.

- Generally, patient should be informed of a possible nonresponse.
- Excellent results (complete or nearly complete abolition of spasm) are

expected in three-quarters of patients at 1 month after operation.

- Long-term follow-up reveals more patients with total relief of their spasm.
- Patients having reoperation should expect lower results: 61% complete or nearly complete abolition of spasm.
- If the patient is still having spasm in the postoperative period, conservative follow-up will usually show progressive resolution of the residual spasm within the following month.

## 8.

- General complication related to posterior fossa surgery
- Specific to facial nerve microvascular decompression:
  - Partial or complete, temporary or permanent facial palsy may result from manipulation of the facial nerve.
  - Owing to the immediate proximity of the eighth cranial nerve, microvascular decompression of the facial nerve for hemifacial spasm has a risk of producing ipsilateral hearing loss of various degrees. This may result from stretching the eighth cranial nerve between its exit from the brainstem and its entry into the internal auditory meatus as the surgeon places cerebellar retraction to expose the facial nerve root exit. This complication may be controlled if intraoperative brainstem auditory evoked potentials are monitored.

## Case 9

### 1.

- Cervical radiculopathy
- Brachial plexopathy
- Peripheral nerve damage
- CRPS

### 2.

- Electromyography with nerve conduction studies (EMG/NCS) may help distinguish a peripheral nerve injury, cervical radiculopathy, and neuralgic amyotrophy.
- This test should be performed a minimum of 3-weeks postinjury to permit appropriate denervational changes, if any, to occur in the affected muscles.

### 3. CRPS is a neuropathic pain syndrome that requires

- Persistent pain beyond that expected from an initial noxious stimulus
- Pain that exceeds the confines of a single peripheral nerve or nerve root

distribution

- Swelling, temperature changes, abnormal coloration, or vasomotor dysfunction in the affected region
- Absence of another condition that could reasonably explain the findings
- CRPS type I has no evidence of nerve injury, whereas in CRPS type II there is evidence of nerve injury, typically upon EMG/NCS.
- With negative EMG findings, this patient has CRPS type I.

#### 4.

- Effective treatment of CRPS requires a multidisciplinary, pain management-oriented approach.
- Aggressive physical therapy enables recovery of function in the affected extremity and prevent disuse changes from occurring.
- Analgesics, typically the anticonvulsants, antidepressants, and opioids, provide pain relief to permit physical therapy (which would otherwise be too painful without them) to be undertaken.
- Psychological evaluation, and ongoing support if needed, is performed to determine whether any psychological amplifiers of pain exist, such as stress, behavioral problems, depression, disordered coping mechanisms, etc., and treat them if necessary.

#### 5.

- If several weeks of the noninvasive multidisciplinary approach are insufficiently helpful, then the patient may be a candidate for anesthetic blocks to provide temporary pain relief.
- If a more aggressive approach is required, then the patient becomes a candidate for SCS.

#### 6.

- The spinal cord stimulator array, either a percutaneous or a laminectomy paddle lead, may be placed in the dorsal epidural space from C2–C5, just off midline and eccentric to the right. C-arm radiography is used to determine the exact location.
- In this location, the stimulator will administer electricity to the dorsal columns associated with the right upper extremity. Thus, the patient should experience stimulation paresthesias in the right arm, overlapping with the painful area.
- Ideally, this is performed in the awake patient to confirm overlap and limit unwanted stimulation paresthesias to other parts of the body such as trunk and leg.



7.

- Displaced electrodes (21.5%)
- Fractured electrode (5.9%)
- Infection (3.4%)
- Hardware malfunction (4.9%)
- Subcutaneous hematoma (4.4%)
- Discomfort over pulse generator (1.2%)
- Cerebrospinal fluid leak (0.5%)

8.

- A meta-analysis of 25 case series with a median follow-up of 33 months found that 67% of CRPS patients achieved 50% or more pain relief.
- SCS is an appropriate and effective therapeutic option for patients with chronic benign pain refractory to medication.

### **Case 10**

B. Turtle.

Turtle headaches are generalized or bifrontal, short-lived headaches noted on awakening as the person sticks his head, turtle-like, out from under the covers. They are associated with sleeping with covers over the head and appear to be related to hypercapnia, producing increased cerebral blood flow, with concomitant hypoxia.

### **Case 11**

1. The syrinx is managed expectantly. No treatment for the syrinx is needed as it does not cause any pressure on the spinal cord or neural elements.

2.

- Multiple sclerosis
- Cerebral palsy
- Spinal dysraphism
- Amyotrophic lateral sclerosis
- Traumatic brain injury
- Stroke

3. Ashworth grading system:

0. No increase in tone

1. Slight increase in tone with small “catch” when moving affected limb

2. More marked increase in tone with easy passive movements

3. Significant increase in tone with hard passive movements

4. Rigid affected part

4.

- Dantrolene

- Decreases calcium influx in sarcoplasmic reticulum

- Decreases muscle contractions

- Progabide

- GABA A and B activator

5.

- Baclofen and morphine pumps.

- Electrical stimulation via epidural electrodes.

- Selective posterior rhizotomies.

- Intramuscular phenol neurolysis.

- Myelotomies.

- Stereotactic thalamotomy.

6.

- Mechanical

- Underinfusion

- Catheter occlusion, kinking, dislodgment, break

- Wound problems

- Erosion of pocket

- Infection

- Local pain

- Seroma/hematoma

- CSF collection

7. Selection criteria for baclofen pump are described below:

- Age 18 to 65, able to give informed consent

- Severe chronic spasticity >6 months

- Spasticity refractory to oral medications

- Ashworth scale at least 3

- No CSF block

- Positive response to intrathecal baclofen test dose

- No implantable device

- Nonpregnant patient
- No allergy to baclofen
- No history of stroke, renal insufficiency, severe liver or gastrointestinal disease.

## Case 12

### 1. B. Orthostatic hypotension

Patients with PD frequently have orthostatic hypotension. This is why they cannot easily get up from a seated position. When rising, the autonomic nervous system is slow to respond. The normal increase in pulse rate and vasoconstriction is not occurring. When a normal person stands, the baroreceptors in the carotid sinus and atria sense the decrease in pressure or stretch. Because these are mechanoreceptors, firing is decreased. The medulla does not perceive the change in posture and there is no output to the sinoatrial (SA) node to increase firing or to the arterioles to contract. Hence, BP is abnormally low when standing and patients can experience syncope. This is like “cogwheel rigidity” of the autonomic nervous system.

#### Response to standing

Normal: vasoconstriction and tachycardia

PD: inappropriately low pulse rate.

In PD, phase 4 depolarization of the SA node stays abnormally flat.

Anticholinergic agent (benztropine, trihexyphenidyl).

The mechanism by which anticholinergic improve PD is unknown.

Why does decreasing acetylcholine increase dopamine? We do not know!

### 2. B. Memory difficulty.

Acetylcholine helps with memory formation. Inhibition of acetylcholine (ACh) will provoke dementia. This is why anticholinergic medication like benztropine is hard to use in those older than 65 to 70 years old. It worsens Alzheimer disease. This is why we use drugs like donepezil, rivastigmine, and galantamine for Alzheimer disease. They increase ACh and improve memory. In addition, inhibiting ACh should cause tachycardia, constipation, and dilate pupils.

More ACh = More memories

Less ACh = Less memories

Anticholinergics worsen glaucoma  
Dilate pupils = Blocked canal of Schlemm

### 3. B. Ropinirole or pramipexole

These medications are direct-acting dopamine receptor agonists. They have less efficacy than levodopa/carbidopa, but they have less adverse effects as well. The standard of care in most PD is to try a dopamine receptor agonist at the beginning of treatment.

Bromocriptine is a dopamine agonist but is a derivative of ergot, and thereby has more adverse effects, such as nausea and vomiting. In choosing treatment, if two medications have the same efficacy, use the one with less adverse effects.

Selegiline is a monoamine oxidase (MAO) inhibitor. This class of drugs decreases the metabolism of dopamine, but the efficacy is unclear.

Amantadine efficacy is limited.

Amantadine may increase dopamine release from the substantia nigra.

You start ropinirole and see the patient again in 2 weeks. He has modest improvement in mobility and orthostasis. Over the next year, he is stable then begins to deteriorate again. You now add levodopa/carbidopa, and he markedly improves.

### 4. B. Inhibition of dopamine decarboxylase.

Levodopa normally has a very short half-life. It, therefore, will decompose and not allow transfer across the blood brain barrier into the brain. Carbidopa is a peripheral dopamine decarboxylase inhibitor. This allows a greater level to enter the brain.

You see the patient at 2-week intervals and increase the dose of levodopa/carbidopa. Perform a neurological examination and check for orthostasis at each visit. The patient is not fully controlled after 2 months.

### 5. B. Add tolcapone or entacapone.

Tolcapone or entacapone are COMT inhibitors. They block the metabolism of dopamine in the brain. They enhance activity of dopamine at the substantia

nigra. They have definite efficacy but are exclusively an add-on therapy to levodopa/carbidopa. They will not work by themselves.

After a few days on the new medications, the good news is, the patient has much better mobility. The bad news is, he has started to develop visual hallucinations and sees “bugs coming out of the walls”.

### 6. C. Dopamine increases psychosis.

The difficulty of medicating patients with PD is that the massive increase in dopamine can cause psychosis in some patients. The dose needed to control PD may mean that the only way to get the PD controlled is to give enough dopamine even though it may lead to the adverse effect of psychosis. The treatment is quetiapine, which is an antipsychotic medication with the lowest amount of parkinsonian adverse effects.

Anti-Parkinson disease (PD) medications cause psychosis.  
Antipsychosis medications cause PD.  
Anti-PD medications cause dementia.  
Anti-dementia medications cause PD.

### Tremor

Type of tremor	Resting tremor	Tremor with intention (action) only	Tremor both at rest and with intention
Diagnosis	Parkinson's disease	Cerebellar disorders	Essential tremor
Treatment	Amantadine	Treat etiology	Propranolol

### Case 13

1. Most likely diagnosis: Parkinson disease.
2. Next diagnostic step: Do an MRI of the brain to evaluate other disorders in the differential diagnosis.
3. Next step in therapy: If the current symptoms are causing the patient disability, initiate therapy with either dopamine agonist or monoamine oxidase type B (MAO-B) inhibitor.

### Considerations

The patient described in the case above has tremor at rest, rigidity, and

hypokinesia, which are the three cardinal features of Parkinson disease—and constitute the syndrome of parkinsonism. The fourth of the cardinal features is postural instability, which in idiopathic Parkinson disease typically has onset several years later. The most common cause of parkinsonism is idiopathic Parkinson disease. A careful search for secondary causes of parkinsonism should be undertaken such as a history of medication use (antipsychotic agents), metabolic or structural diseases of the brain (hydrocephalus), and infectious etiologies. MRI of the brain is typically performed. Levodopa is a standard agent used to treat the symptoms of Parkinson disease; unfortunately, no agent has been shown to slow the progress of the disease.

## APPROACH TO SUSPECTED PARKINSON DISEASE

### Definitions

Substantia nigra or locus niger is a heterogeneous portion of the midbrain, and a major element of the basal ganglia system. It consists of the pars compacta, pars reticulata, and the pars lateralis.

Lewy body—an eosinophilic, round inclusion found in the cell cytoplasm of substantia nigra, the nucleus basalis of Meynert, locus ceruleus, dorsal raphe, and the dorsal motor nucleus of cranial nerve X. They contain alpha-synuclein, a presynaptic protein, the function of which is unknown. Neurofilament proteins and ubiquitin are other important constituents of Lewy bodies.

### Clinical approach

Parkinson disease is a disorder that gets its name from the Essay on the Shaking Palsy by James Parkinson. Features of Parkinson disease can be expressed in other ways including: difficulty arising from a chair, difficulty turning in bed, micrographia, masked face, stooped, shuffling gait with decreased arm swing; and sialorrhea. Although Parkinson disease is thought of as a motor disorder, sensory systems are also affected. Loss of sense of smell is almost universal. Pain is very common. Other system involvement can result in autonomic disturbance, depression, a variety of speech disturbances including dysarthria, palilalia, and stuttering. In Parkinson's monograph, he specifically stated "the senses and intellect are preserved."

Research has shown that isolated cognitive deficits are extremely common in Parkinson disease, especially executive dysfunction. In addition approximately 50% of patients develop dementia.

The most obvious pathologic feature of Parkinson disease is loss of pigment in the substantia nigra caused by loss of neurons in this region. The remaining neurons may show an intra-cytoplasmic eosinophilic inclusion called a Lewy body. These neurons project rostrally in the brain to innervate the striatum as well as the cerebral cortex. Parkinson disease is associated with marked striatal dopamine (DA) depletion and is considered by many to be a striatal dopamine deficiency syndrome. At death, DA loss is greater than 90%, and approximately 70% DA loss results in symptom expression. Severity of DA loss best correlates with bradykinesia in Parkinson disease—the correlation with tremor is very poor. In recent years, we have seen a much more comprehensive picture of the pathologic destruction by Parkinson disease, which helps us to understand the wide variety of signs and symptoms besides bradykinesia.

Other morphologic and chemical deficits have also been demonstrated in the brains of patients with Parkinson disease in the cholinergic pedunculopontine nucleus, noradrenergic locus coeruleus, serotonergic raphe nuclei, and glutamatergic centromedian/parafascicularis complex of the thalamus. Still, there are many signs and symptoms that are atypical for Parkinson disease and should raise our level of vigilance that another disorder is present. These include:

- Early onset of, or rapidly progressing, dementia
- Rapidly progressive course
- Supranuclear gaze palsy
- Upper motor neuron signs
- Cerebellar signs—dysmetria, ataxia
- Urinary incontinence
- Early symptomatic postural hypotension
- Early falls

The majority of cases of Parkinson disease are unknown. Familial Parkinson disease, while rare, does occur, and is most commonly associated with a mutation of the parkin gene, which is inherited in an autosomal recessive pattern.

This mutation is the most common cause of early onset Parkinson disease, without Lewy bodies. Routine neuroimaging is usually normal in Parkinson disease. Functional imaging designed to visualize the dopamine innervation of the striatum, especially in combination with other imaging techniques may provide a way to positively identify the disease, however these techniques are still under investigation and are not available under routine clinical

circumstances. Imaging is useful, however, to identify some of the other entities in the differential diagnosis. The differential diagnosis of parkinsonism includes the following categories:

- Drug-induced (antipsychotics, metoclopramide)
- Toxin-induced
- Metabolic
- Structural lesions (vascular parkinsonism, etc.)
- Hydrocephalus (normal-pressure hydrocephalus [NPH])
- Infections

### Differential diagnosis

Parkinson disease is most often mimicked by other neurodegenerative disorders, most commonly by multiple system atrophy (MSA). This comes in two major clinical forms: MSA–P, resembles Parkinson disease except that tremor is less prominent, and the disorder tends to be quite symmetric. MSA–C, also called olivopontocerebellar atrophy, presents as a cerebellar syndrome. Both forms may have prominent autonomic insufficiency—including orthostatic hypotension and impotence. Conventional MRI usually show abnormalities.

Dementia with Lewy bodies is a disorder with prominent cognitive dysfunction as well as parkinsonism. The typical clinical hallmarks include early onset dementia, delusions and hallucinations, fluctuations in consciousness and myoclonus. Although listed as a separate entity, there is much controversy about whether this is Parkinson disease or represents parts of the clinical spectrum of the same pathologic entity. Although parkinsonism can be seen in Alzheimer disease, it is a rare finding, and dementia is usually the primary clinical syndrome.

Corticobasal ganglionic degeneration typically has unilateral, coarse tremor, rigidity, increased reflexes as well as limb apraxia/limb dystonia/alien limb phenomenon. This disorder is the only one that typically has the asymmetric appearance of Parkinson disease. Progressive supranuclear palsy is characterized by supranuclear downgaze palsy (inability to voluntarily look down) and square wave jerks on extraocular motion testing. These patients typically have an upright rather than flexed posture. Also frequent falls can be an early finding. Tremor is not common, and there is a pseudobulbar emotionality. As mentioned, several drugs, especially dopamine antagonists (typical neuroleptics, anti-nauseants) can cause drug-induced parkinsonism.



## Treatment options

Treatment is initiated when the patient's quality of life is affected and usually consists of either levodopa or a dopamine agonist. Because no treatment currently arrests the degenerative process, symptomatic treatment is the mainstay of therapy. This includes pharmacologic and surgical interventions. Physical measures such as physical therapy, speech therapy, and exercise are important and have a major impact on the lives of patients with Parkinson disease.

### Pharmacologic therapy

- Dopaminergic agents are the mainstay of treatment for the cardinal features of Parkinson disease.
- Levodopa crosses the blood–brain barrier, whereas dopamine goes not; levodopa is converted to dopamine in the brain. Peripheral breakdown in the gut is inhibited by the addition of inhibitors of aromatic amino acid decarboxylase (dichloroisoprenaline [DCI]), carbidopa. Thus, a Carbidopa/Levodopa formulation is popularly prescribed. Levodopa can also be broken down peripherally by the enzyme catechol-O-methyltransferase (COMT) so COMT inhibitors such as entacapone and tolcapone are often employed. A therapeutic trial of levodopa can confirm Parkinson disease because more than 90% of patients with pathologically proven Parkinson disease have a good to excellent response to adequate doses of levodopa (at least 600 mg/d levodopa with DCI).
- Dopamine agonists cross the blood–brain barrier and act directly as primarily D2-type receptors without requiring conversion. These agents include pramipexole, ropinirole, and bromocriptine.
- MAO-B inhibitors such as selegiline and rasagiline can improve symptoms in both patients with mild disease (as monotherapy) and patients already on levodopa therapy. Anticholinergics such as trihexyphenidyl or diphenhydramine (Benadryl) are used primarily to combat tremor, but have many side effects especially in older individuals.
- Amantadine is felt to act primarily by blocking glutamate N-methyl-D-aspartate (NMDA) receptors and has a mild attenuation of the cardinal symptoms of resting tremor and dystonia. Recently, amantadine has been shown to help alleviate levodopa induced dyskinesias.

Although no treatment slows the degeneration of Parkinson disease, disease mortality has been reduced by levodopa therapy. Over time, the response to levodopa becomes unstable, resulting in motor fluctuations, which are exaggerated clinical manifestations; also, patients can develop troublesome abnormal involuntary choreiform and dystonic movements called dyskinesias.

There is good evidence that starting treatment with a dopamine agonist rather than levodopa delays the onset of dyskinesias. Thus, those patients at high risk for developing dyskinesia probably should be treated initially with dopamine agonists.

Younger patients are more at risk for dyskinesia and are likely to be treated for long periods of time (the average age of onset of Parkinson disease is approximately 59 years). Although levodopa is the most efficacious agent for the treatment of Parkinson disease, for mild Parkinson disease, dopamine agonists have comparable benefit. In patients that still have an excellent response to levodopa except for motor fluctuations and dyskinesias, surgical treatment that inhibits the subthalamic nucleus with high-frequency stimulation can provide excellent relief of the cardinal symptoms of disease.

However, placement of a deep brain stimulation (DBS) appears to be the preferable surgical therapy. It is less invasive, more reversible, and can be adjusted to the individual patient, and remarkable results can be seen. In addition, inhibition of the ventrolateral thalamus can be very effective for treatment of tremor.

## **Case 14**

D. No investigation is needed to confirm the diagnosis.

Given the age of the patient, symmetry of the tremor, its frequency, location, and response to alcohol, benign essential tremor is a reasonable option; so no need to embark on any investigation as the diagnosis is clinical and there are no atypical features (like extensor plantars).

## References

1. P.A. Starr, N.M. Barbaro, P.S. Larson. Neurosurgical operative atlas. Functional neurosurgery. Thieme Medical Publishers, 2d Ed., New York, 2009.
2. C. Sommer, D.W. Zochodne. Case studies in neurological pain. Cambridge University Press, New York, 2012.
3. H.T. Benzon, S.N. Raja, S.S. Liu, S.M. Fishman, S.P. Cohen. Essentials of pain medicine. 3rd Ed., Elsevier Saunders, Philadelphia, 2011.
4. J.D. Hoppenfeld. Fundamentals of Pain Medicine. Wolters Kluwer Health, Philadelphia, 2014.
5. S.M. Hayek, B.J. Shah, M.J. Desai, T.C. Chelimsky. Pain medicine : An Interdisciplinary Case-Based Approach. Oxford University Press, New York, 2015.
6. Kim Burchiel. Surgical Management of Pain. Thieme Medical Publishers, 2nd Ed., New York, 2014.