

EANS/UEMS European examination in neurosurgery

Variants of questions with answers (compilation - Vyacheslav S. Botev, Department of Neurosurgery, M.Gorky Donetsk National Medical University)

CASE HISTORIES IN TRAUMATIC BRAIN INJURY

Questions

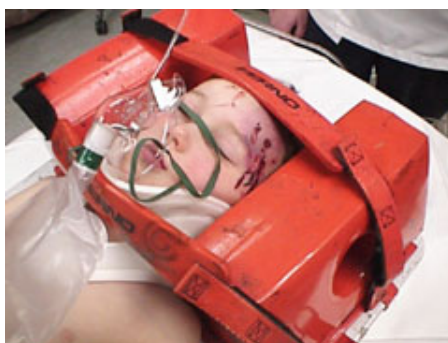Case 1

07:00 AM

Kiev

Level One Trauma Centre

We've got a 12-year-old boy, rear seat unrestrained passenger. Ejected from the car through the front windshield after a frontal impact, combined speed around 120 km/h. The mother's still trapped in the car. The kid's breathing but he's unresponsive. We just scooped him onto the spine board and ran him in here. The boy is strapped to the spine board with a cervical collar and a reservoir oxygen mask in place.



You ask your intern Alexander to attach some monitoring while you start your assessment. You try to speak to the boy but he remains unresponsive.

There does not seem to be any injury to the face and there is only a little clear sputum in the pharynx which you suck out (which does not provoke any gagging). Little air is being shifted and there are obstructive, stridor-like noises on inspiration.

You decide to intubate the child, recognising his obstructed and unprotected airway. "I'm going to intubate him, Alex, hand me a laryngoscope and a tube". Alex hands you a straight bladed laryngoscope, which you throw back at him. "Straight blades are for infants, Alex, you should know that". Alex immediately starts behaving like an infant and goes into one of his "moods". "Sorry, I'm sure.

What size tube do you want? I'm sure you know what size tube a 12-year-old needs”.

Questions:

1. You do know what size tube you want. Don't you?

With cricoid pressure you get a good view of the cords.

Good. The tracheal tube is in the right place and the patient is ventilating well.

Primary Survey

Airway: Intubated and ventilated.

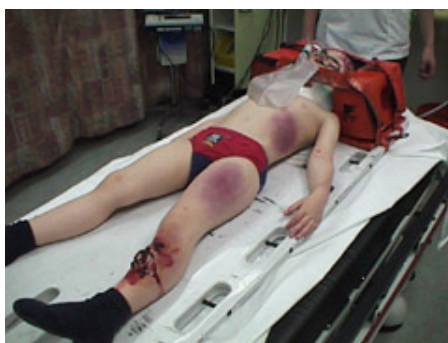Breathing: RR 24/min. Oxygen saturation 92%.

Trachea central. Equal air entry bilaterally.

Circulation: Heart Rate 90, BP 80/50.

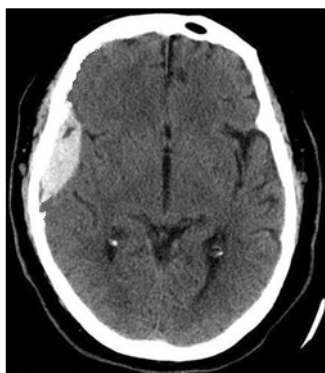
Dysfunction: GCS 9 (E3V3M3), Pupils equal & reactive.

Exposure: There's some minor bruising over the left chest and upper abdomen and an obviously broken and deformed left femur and tibia, with an open wound over the shin:



2. What studies should you obtain?

A CT scan of the brain was performed:



3. What is your diagnosis?

4. In which population is it rare to see epidural hematomas (EDH)?
5. Is the source of bleeding of the EDH always arterial?
6. What is the most common location of EDH?
7. What is the classic CT appearance of EDH?
8. What are the indications for surgical evacuation of an EDH?
9. Why are epidural hematomas more frequently seen in younger adults than in the elderly?
10. How are epidural hematomas different in children and adults?

Case 2

07:30 AM

Kiev

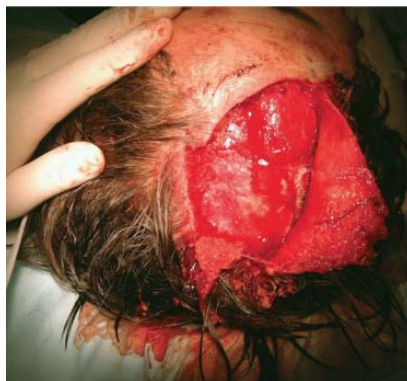Level One Trauma Centre

It's the last day of your rotation. You are doing a case completely by yourself in the simulator. You are surprised by how nervous you felt in the beginning, as if the patient you are caring for is not the mannequin in front of you but a real patient. But there is no attending guiding you, and you've heard that sometimes things go very wrong in the simulator. You've not being graded, but you are being videotaped, and you know that your fellow students and the instructors will be reviewing your performance. But so far it's been a quiet case.

Your "patient" is a 28-year-old police officer. He is brought to the emergency room by ambulance following a high-speed motor vehicle collision.

You perform your primary survey:

Airway:	Maintaining own.
Breathing:	RR 22/min. Oxygen saturation 95%. Trachea midline. Clinical # L ribs. No emphysema. Equal air entry bilaterally.
Circulation:	Cool, Pulse non palpable, ECG – HR 120, BP unrecordable.
Dysfunction:	GCS 10 (E3V3M4), Pupils equal & reactive.
Exposure:	L Forehead wound that is bleeding copiously:



You place 2 large bore IV luers, a right subclavian line, and then sequentially you put up 1L of Normal Saline. Not forgetting the Tetanus booster. The saline is running well through a peripheral line.

The secondary survey shows:

Head – L Forehead wound

Neck – In hard collar

Chest –L ribs #, No surgical emphysema, equal BS

Abdo - Hard

Pelvis – Tender, but not mobile

Limbs – Laceration L leg, Hematoma R arm

Log Roll – No vertebral steps or pain

Trauma series:

CXR: L 4th, 5th, 6th ribs #, no pneumothorax, normal mediastinal width, irregular shaped right hemidiaphragm.

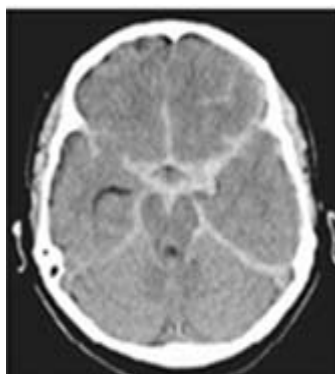Pelvis AP: Posterior dislocation fracture right acetabulum.

C-Spine: No apparent fracture on lateral view, showing the C-spine only down to C6. Formally inadequate X-Ray.

CT Chest: Right-sided pulmonary contusions, undisplaced right scapula blade fracture.

CT Abdo: No solid organ injuries, no free fluid, small amount of fluid around the right kidney, hematoma in the area of the acetabular fracture.

A CT scan of the brain is performed:

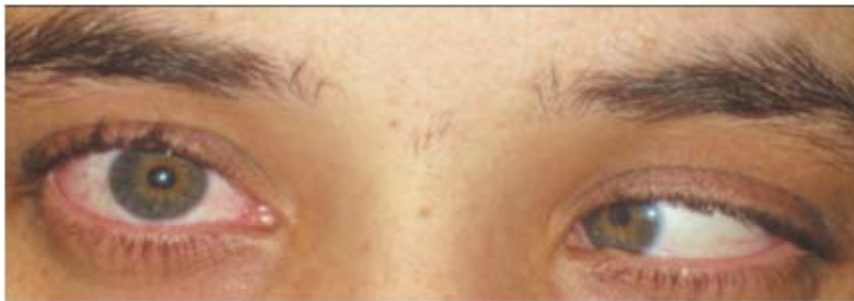

Questions

1. What is the most common cause of the finding on this CT image?
2. Which factor has the greatest predictive value in the development of seizures following head trauma?
3. What is the leading cause of death and disability in trauma victims?
4. When is intubation indicated in a patient with a reduced level of consciousness?
5. How should the patient be managed in the emergency department?

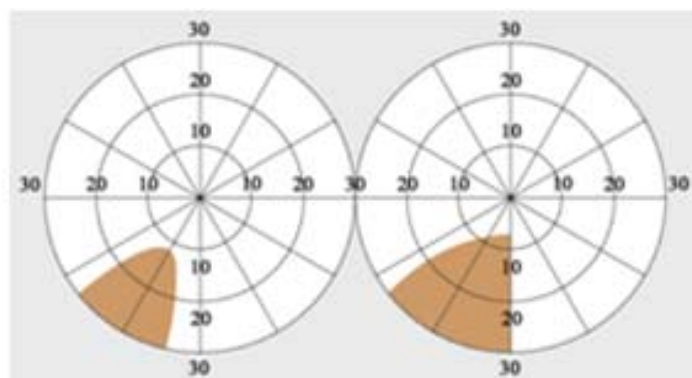
The next morning you check his condition in ICU.

The patient was trying to look right when the image was taken:



6. What is the diagnosis?

Five days later assessment shows the presence of a left inferior homonymous hemianopsia:



7. Where is the lesion located?

Case 3

10:15 AM

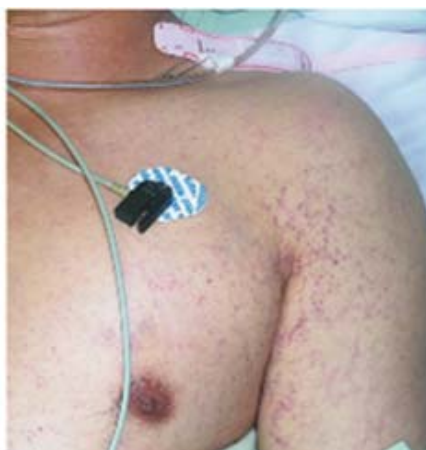Kiev

Level One Trauma Centre

You graduated with top honors in both college and medical school and now you have a very demanding, high stress job as a second year general surgery resident covering trauma in a large hospital.

You stabilize a multiple trauma victim whose injuries include mild head injury, scalp lacerations, and the left femoral shaft fracture. He was unresponsive to verbal stimuli, and no focal neurologic abnormalities were found on examination. An arterial blood gas analysis revealed mild hypoxemia, but a radiograph of the chest was normal. Tracheal intubation was performed for airway protection.

Seven hours after presentation, widespread petechiae developed on the chest, upper arm, and armpit:



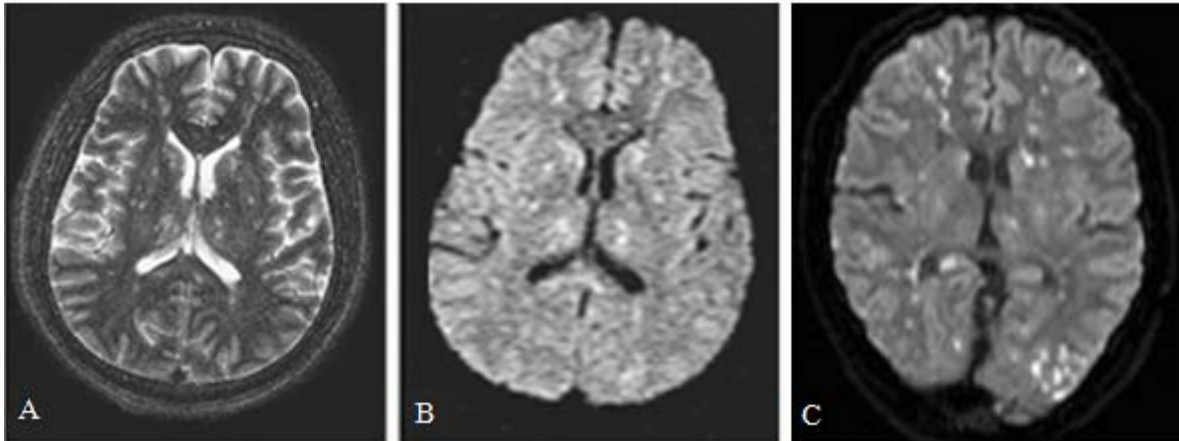
Questions

1. What is the most likely diagnosis?
2. What is the most likely cause of this man's symptoms and why?
3. What are the classification systems of FES?

The victim's oxygen saturation has dropped to the low 90s and the urine output is declining.

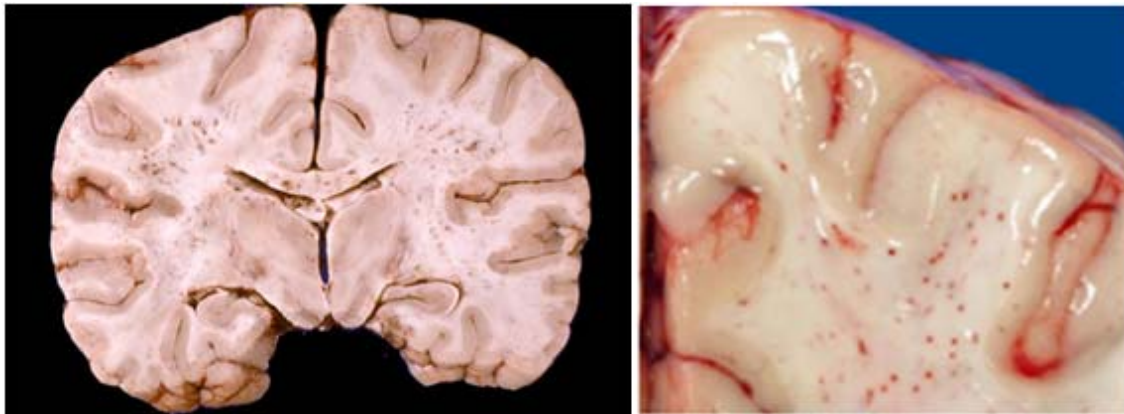
4. What is the likely cause of the respiratory failure?
5. What is your initial management?

6. Magnetic resonance imaging of the brain is performed. Describe the appearances.



7. What is the “starfield pattern”?

The patient expires 4 days later of respiratory insufficiency. A horizontal section of the patient’s brain at autopsy reveals numerous petechiae scattered throughout the white matter:



8. What is the most likely explanation for this pathologic finding?

Case 4

03:45 AM

Kiev

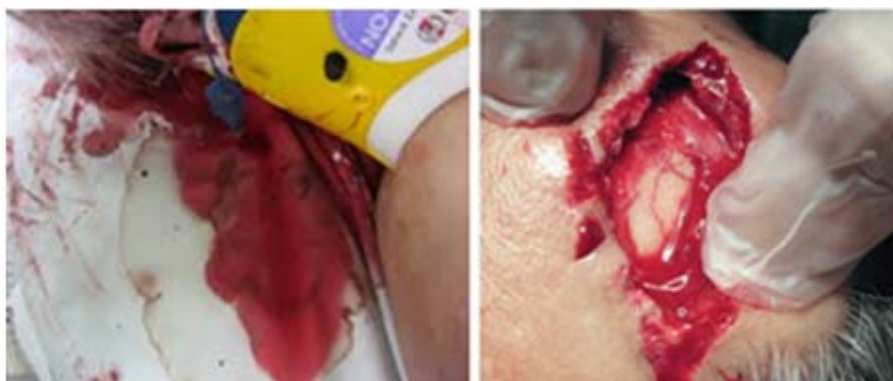Level One Trauma Centre

It's my first night on call alone, all by myself, since the beginning of my neurosurgery residency training. Of course, I'm scared out of my mind! I'm watching the clock, quietly counting the minutes until the night is over, and praying that I won't accidentally kill anyone with my lack of experience.

A female voice screams into my pager, "We need you *now* in ED room 3". On scene paramedics inform you that they are with a 26-year-old male who was the restrained driver (no airbag) of a saloon car that had an argument at 85km/h with a telegraph pole and lost. The driver has been trapped in the car for around 30 minutes but is now free and has a scalp wound and he is somewhat aggressive (Glasgow Coma Score 10 – E3V3M4). They will be with you in ten minutes.

Primary Survey

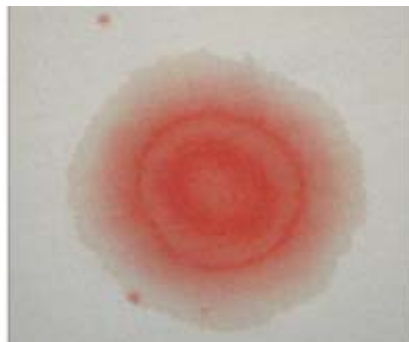
Airway: Clear.
Breathing: RR 24/min. Oxygen saturation 99%.
 Trachea central. Equal air entry bilaterally.
Circulation: Heart Rate 80, BP 130/70.
Dysfunction: GCS 10 (E3V3M4), Pupils equal & reactive.
Exposure: Right-sided bloody otorrhea, L Forehead wound:



You place two large bore (14G) intravenous luers, a right subclavian line, and then sequentially you put up 1L of Normal Saline. Not forgetting the Tetanus booster. The saline is running well through a peripheral line.

Questions

1. What is the specific pattern produced by bloody otorrhea can you see on a bedsheet of this patient (picture below)?

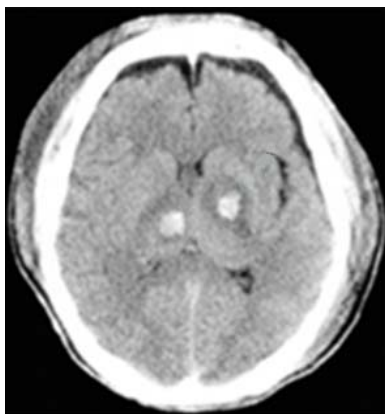


What next, professor?

Right, you begin your head to toe secondary survey.

2. What is a secondary survey and what does it include?

A CT scan of the brain is performed and shown below:



3. What is the most likely diagnosis?

4. What are the areas most prone to this injury after head trauma?

5. What is the microscopic hallmark of this pathology?

Case 5

5:38 PM

M4, Junction 3, accident scene.

It's a sunny Sunday in November. You are a general surgery R3 covering neurosurgery trauma.

At 5:28 PM a motorcyclist travelling at around 110 km/h lost control of his bike and went into the back of a stationary vehicle on the side of the motorway. He was apparently thrown some 15-20 meters from the bike.



Primary survey at scene @ 0540:

Airway: Obstructed.

Breathing: Absent.

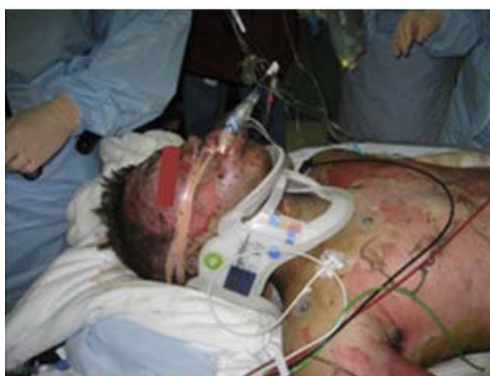Circulation: Weak radial pulse, ~80mmHg.

Disability: GCS 3/15 (E1V1M1).

Pupil: left 3.0 mm, right not check due to periorbital swelling.

Exposure: Compound # (L) forearm, R Forehead wound.

There is extensive bruising to both sides of the chest.

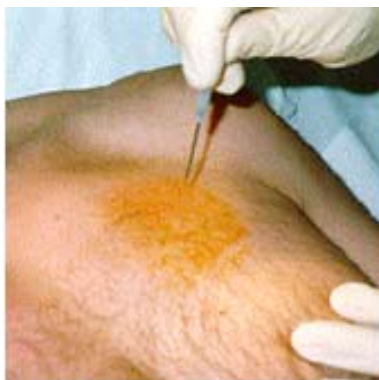

C-spine immobilized with hard collar. Airway cleared by direct laryngoscopy. Patient intubated and ventilated while sitting.

Examining the patient's ventilation you notice the trachea is deviated to the right and the right chest sounds duller to percussion than the left. Breath sounds are reduced on the left. Something's obviously going on in his chest. You need to do something definitive pretty quickly.

Questions

1. What do you think is going on?
2. What do you want to do first, professor?
3. Will you insert a left-sided chest drain immediately?



Right. You place a needle thoracostomy in the left chest anteriorly. A satisfying hiss of air escapes and the patient's ventilatory pattern improves. A tension pneumothorax is a clinical, not radiological diagnosis. If you suspect it you should act on it immediately, as delay may be fatal. But you know that already. He'll need a left chest tube a bit later. You place two large bore (14G) intravenous lines. You assess his circulatory state.

Fluid Resuscitation: Hartmanns, Haemaccel, Fresh frozen plasma (FFP), Crystalloids.

Drugs prehospital:

Adrenaline 3 mg,

Atropine 1 mg,

Sodium Bicarbonate 50 mmols.

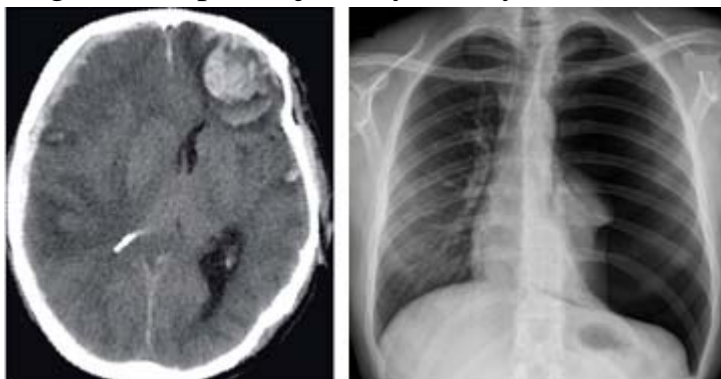4. Will you go with this or have you got a better idea?

Time to get some CT and X-rays.

Which X-rays do you want?

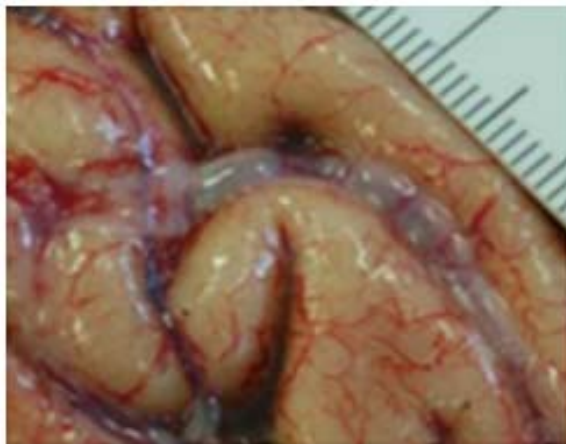
5. The CT scan of the brain and chest X-ray are performed.

Describe the findings. Don't panic, just say what you see.



6. What is the most likely diagnosis?
7. What is your initial management?

The patient expires after 3 weeks in a coma.
This gross appearance is found at autopsy:



8. What is your diagnosis?
9. How is this pathology treated?

Case 6

A 48-year-old woman. Back seat passenger in 70km/h head-on collision. Driver and front seat passenger pronounced dead at scene. Difficult extrication. Paramedics have intubated her and administered 1.5L intravenous fluids via two large-bore cannulae.

Primary Survey

- Airway:** Intubated and ventilated.
Breathing: Trachea central. Bilateral, equal air entry, RR 35.
Circulation: Heart Rate 120, BP 80/50.
Dysfunction: GCS 7 at scene. Left pupil dilated. Bruising over right orbit.
Exposure: No other obvious external injury.

Ultrasound scan of the abdomen reveals free fluid in the peritoneal cavity.

Question:

1. Definitive therapy begins with:
 - A. Laparotomy
 - B. CT scan of the brain
 - C. Craniotomy
2. Simultaneous intracranial and abdominal injury: which gets operated on first, and which was the higher treatment priority?

Case 7

A 44-year-old male patient, driver in a head-on motor vehicle collision. Trapped in his car for 20 minutes at scene. Extricated on a long spinal board following roof removal.

**Primary Survey**

- Airway:** Intubated and ventilated.
- Breathing:** Trachea central. Bilateral, equal air entry, RR 32.
- Circulation:** Heart Rate 70, BP 110/70.
- Dysfunction:** GCS (pre-intubation) 9 (E2V3M4).
Pupils equal & reactive. Bruising over left orbit.
- Exposure:** No other obvious external injury.

The patient arrives fully immobilised on a long spinal board with sandbags and semi-rigid collar in place.

Question:

When would you take the patient off the long spine board?

- A. After the primary survey
- B. After full set of spinal X-ray
- C. Once he's regained consciousness and the spine can be cleared clinically.

Case 8

A 52-year-old nocturnal roofing engineer falls 3 stories onto grass.

Primary Survey

Airway: Patent.
Breathing: RR 20/min. Oxygen saturation 99%.
 Trachea central. Equal air entry bilaterally.
Circulation: Heart Rate 80, BP 110/50.
Dysfunction: GCS 9 (E3V3M3).
Exposure: (R) arm - deformity, pulse present.
 (R) leg - swollen (R) femur.

Question:

What do you want to do now?

- A. Operate
- B. Ultrasonography
- C. Have dinner and wait
- D. 2 units of O pos blood
- E. Complete a trauma series X-rays

Case 9

It is 7:10 AM. A 34-year-old woman loses control of her car while putting her make-up on. She is not wearing her seatbelt (interferes with mascara application) and has bullseyed the windshield. There is significant damage to the steering column.

Primary survey at scene @ 0718:

Airway: Obstructed.
Breathing: Absent.
Circulation: Weak radial pulse, ~80 mmHg.
Disability: GCS 3/15 (E1V1M1).
Exposure: Compound # (L) forearm.

Treatment: Airway cleared by direct laryngoscopy.

Patient intubated and ventilated while sitting.

C Spine immobilized with hard collar.

IV access obtained.

Fluid Resuscitation:

Hartmanns 4000 mls,

Haemaccel 2000 mls,

Drugs prehospital:

Adrenaline 3 mg,

Atropine 1 mg,

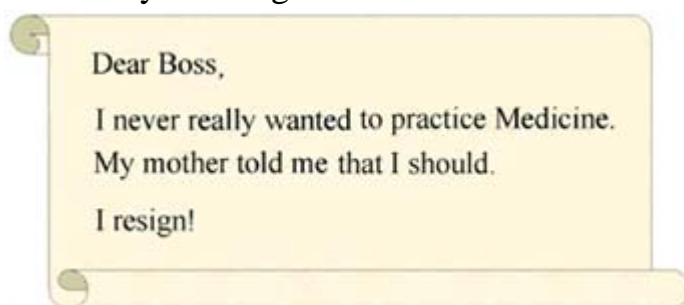
Sodium Bicarbonate 50 mmols.

Initial cardiac rhythm Sinus Bradycardia (SB) deteriorating to Idioventricular rhythm (IVR) then to asystole. Ventricular fibrillation (VF) arrest while still trapped in car @ 0721.

Question:

Sweaty, tachycardic and febrile, you anxiously decide what to do:

- A. Pericardiocentesis
- B. Arterial Line insertion
- C. Complete the spinal X-rays
- D. Defibrillation with 200 joules
- E. Write your resignation:

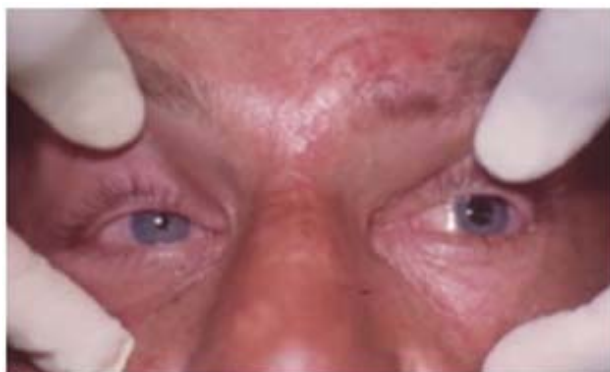

Case 10

It's the Sunday of Labor Day weekend and you are working in the ED. As a senior resident in the ED, an intern calls you over to see a patient, a 42-year-old male, he rolled his car at high speed on the motorway. Difficult extrication. Paramedics have intubated him and administered 1.5L intravenous fluids via two large-bore cannulae.

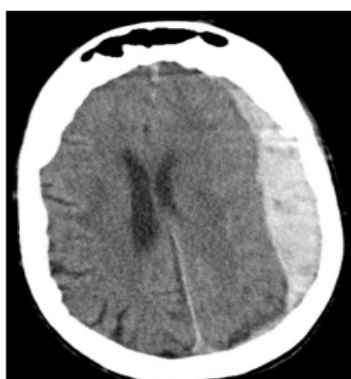
Primary Survey

- Airway:** Intubated and ventilated.
- Breathing:** Trachea central. Equal, moderate air entry, RR 35.
- Circulation:** Heart Rate 120, BP 80/50.
Already given 1.5 litre crystalloid solution.
- Dysfunction:** GCS 7 at scene. Left pupil dilated.
- Exposure:** No other obvious external injury.



Questions:

1. The CT scan is performed. Describe the findings.



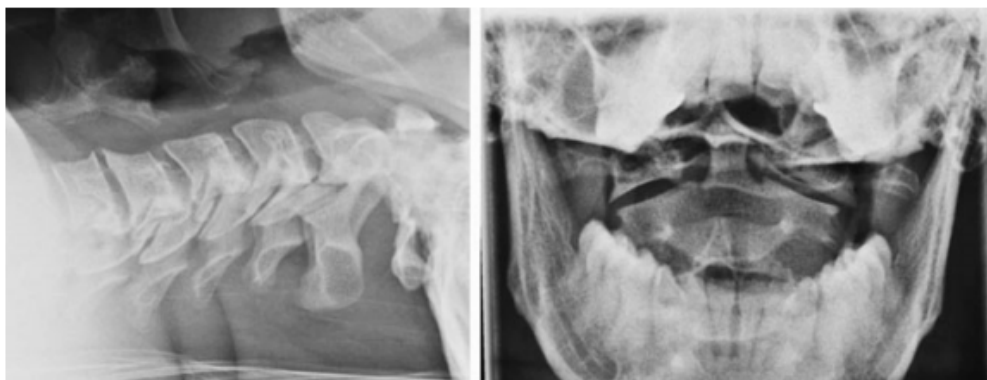2. Why is a subdural hematoma (SDH) more lethal than an EDH?
3. How often is an underlying cerebral contusion seen in SDH?
4. What are the biochemical findings on the brain tissue underlying an evacuated SDH, and what do they indicate?
5. What is the classic CT appearance of acute SDH?
6. Why can acute SDH be hypodense on CT?
7. What is different between SDH and EDH on CT?
8. What are the SDH density changes on CT with time?
9. Is the source of bleeding of the SDH always venous?
10. How can we differentiate an SDH resulting from arterial rupture from those resulting from venous rupture?
11. Is the shape of the hematoma the same between arterial and venous SDH?
12. What is the positive displacement factor?
13. What is the definition of “early” vs. “late” surgery?
14. What is Kernohan’s notch phenomenon?

Case 11

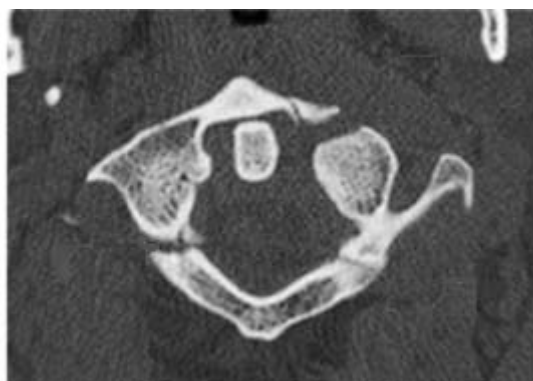
A 39-year-old man was brought to the emergency department after falling off a ladder from a height of approximately 5m. He was unsure how he landed but denied loss of consciousness. He had severe neck pain at the scene and the ambulance crew placed him supine on a board with a hard cervical collar and blocks. On examination, he has a laceration on the forehead. His GCS is 15/15 with no focal neurological deficits. The rest of the physical examination is normal.

Questions

1. How can we decide if this patient should have imaging of the cervical spine?
2. The lateral cervical spine and open-mouth odontoid views are shown below. Describe any abnormalities. What should be done next?



3. The CT scan at the level of the atlas (C1) is shown below.



- a) Describe the abnormalities.
 - b) How might the patient have landed on the ground?
 - c) The patient wants to get up and go for a walk. What would be your advice?
4. How should this patient be managed?
 5. The patient asks what the collar does and whether he can take it off when he showers or goes to bed. How would you advise?

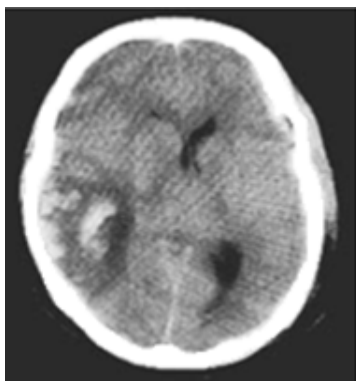
Case 12

A 35-year-old internet entrepreneur jumps from a 3rd floor window and appears to have an isolated head injury.

Primary Survey

Airway: Intubated and ventilated.
Breathing: Bilateral, equal air entry, O₂ sats 96%.
Circulation: Pulse 80/min, BP 160/100.
Dysfunction: GCS 5 (E1V1M3) prior to intubation. Pupils equal & reactive.
Exposure: No other obvious external injury.

CT scan shows a large parietal contusion with some diffuse brain injury.



Arterial Blood Gases show: pH 7.38, PaO₂ 14kPa (105 mmHg), PaCO₂ 5.8 kPa (43.5 mmHg), Base excess -2.8

Questions:

1. His ventilation needs adjusting:

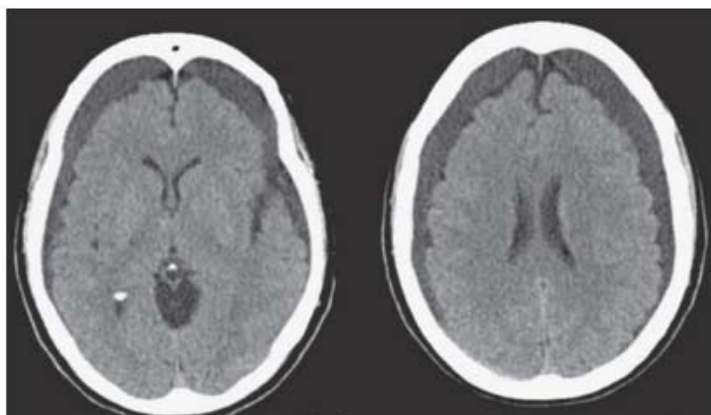- A. Increase ventilation to achieve normocapnia
- B. Increase ventilation to achieve hypocapnia
- C. Decrease ventilation to achieve hypocapnia

2. The cardiovascular effects of raised intracranial pressure include (BP = blood pressure; HR = heart rate; CPP = cerebral perfusion pressure):

- A. ↓ BP, ↓ HR, ↓ CPP
- B. ↓ BP, ↑ HR, ↓ CPP
- C. ↑ BP, ↑ HR, ↓ CPP
- D. ↑ BP, ↓ HR, ↓ CPP
- E. ↓ BP, ↑ HR, ↑ CPP

Case 13

A 70-year-old woman with end-stage Alzheimer's disease is brought to the ER for a 3-day episode of increasing confusion, agitation, and inappropriate behavior. She is a poor historian, but she does report having had frequent falls in the near past. Physical examination reveals a left-sided pronator drift and confusion. The remainder of the examination is normal. Computed tomography (CT) scan is obtained and shown below:

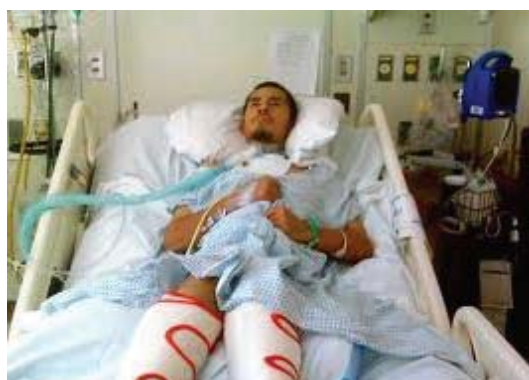

Questions

1. Interpret the CT scan.
2. What are the risk factors for chronic subdural hematomas (CSDH)?
3. What is the pathophysiology of CSDH?
4. How long does it take for the membrane to form?
5. How does CSDH present?
6. What is the management of CSDH?
7. What is important to remember about chronic subdural hematomas?
8. What are the surgical options for CSDH?
9. List the technical pearls to prevent recurrence in CSDH.
10. Which patients have a better outcome with CSDH?
11. Is clinical improvement only achieved if the CT shows resolution of the CSDH?
12. What can be done to treat a persistent recurrent chronic subdural hematoma?

Case 14

Which of the following is consistent with a persistent vegetative state?



- A. Sleep-wake cycles
- B. Absence of any cranial nerve reflexes
- C. Intact bladder and bowel functioning
- D. Consistent eye opening to verbal stimuli
- E. Unawareness of the environment for 3 weeks after injury

Case 15

A 27-year-old man on the ICU underwent decompressive craniectomy 7 days following an acute subdural hematoma. He remains intubated and ventilated and has become agitated with a heart rate of 120 bpm and a BP of 80/40 mmHg. His urine output is 200 ml/h. Further serum and urinalysis reveals the following results:

Serum osmolality 300 mOsm/l;	Na ⁺ 120mmol/l
Urine osmolality 300 mOsm/l;	Na ⁺ 40mEq/l

Which of the following would be the most appropriate next step in your management?

- A. Fluid restriction
- B. Fluid resuscitation with 0.9% NaCl
- C. Demeclocycline
- D. Fludrocortisone
- E. Desmopressin

CASE HISTORIES IN TRAUMATIC BRAIN INJURY

Answers

Case 1

1. A small list of areas to improve on:

- To estimate the child's weight correctly for up to 8 years, you can use: $(\text{Age} \times 2) + 8$, and after this $(\text{Age} \times 3)$.
- Tracheal tube size can be estimated as: $(\text{Age} / 4) + 4$.
If you don't know the age you can size the tube against the terminal digit of the little finger of the child.

2. Complete a trauma series X-ray, CT scan of the brain, follow the ATLS protocol.

3. Epidural hematoma.

4. Before 2 years of age and after age 60; dura is more adherent to the inner table in this group.

5. No; 85% arterial bleeding (middle meningeal artery), and the remainder from bleeding from the middle meningeal vein and dural sinus.

6. 75% laterally over the hemisphere with the epicenter at the pterion. The rest in the frontal, occipital, and posterior fossae.

7. 85% of EDHs are hyperdense biconvex (lenticular) adjacent to skull; in 10% the side against the skull is convex and the side along the brain is straight; in 5% it is crescent shaped.

8.

- Any symptomatic EDH.
- Asymptomatic but >1 cm in its thickest measurement (difficult for the brain to reabsorb).
- In pediatrics, threshold for surgery should be very low.

9. The dura is thinner and more adherent to the skull in the elderly. This decreases the ease with which the dura tears. In relation to an overlying skull fracture epidural hematomas are much more common in children and young adults than in the elderly, probably because of the flexibility of the skull and the readiness with which the dura strips off the bone.

10. In children, epidural hematomas are caused by venous bleeding more often than in adults (where the usual culprit is the middle meningeal artery). In

retrospective studies, it is therefore not surprising that 60% of children and 85% of infants with epidural hematomas had no disturbance of consciousness at the time of injury.

Case 2

1. Trauma to the brain is a common cause of subarachnoid bleeding.

2. Glasgow coma score (GCS) < 8.

The factor most predictive of posttraumatic seizures is a GCS of < 8; 38.7% of patients with a GCS of < 8 will develop seizures compared with 3.8% of patients with a GCS > 8.

3. Brain injury is the most common cause of death and disability in trauma victims.

4. Intubation is indicated if the patient is unable to maintain their airway (and therefore is at risk of airway obstruction or aspiration) or if agitation renders essential supportive therapy (e.g. oxygen, intravenous fluids) or diagnostic investigations (CT scan) impossible. The decision must be made on an individual basis: a postictal patient with a GCS of 7/15 may not need intubation, whereas a patient with a GCS of 13/15 who is combative and needing a CT scan does.

5. This man is a typical polytrauma patient who should be managed according to the ATLS protocol. A fatality in the same accident is a strong predictor of major injury. A trauma call should be undertaken with advance warning of his arrival. An anesthetist should be in attendance to manage the airway. An orthopedic and general surgeon should assess the patient clinically for injuries that need early management before a CT scan is performed. X-rays of the chest and pelvis should be taken in the resuscitation room to exclude a hemopneumothorax or an unstable pelvic fracture that can be stabilized prior to CT scanning. The lateral cervical spine X-ray may be omitted and the cervical spine kept immobilized if the patient is going to have a CT scan to include this area. A senior emergency medicine clinician should attend the trauma call in a supervisory capacity as the “team leader”.

6. Right VI cranial nerve palsy.

7. Right parietal lobe.

A “pie-on-the-floor” lesion is a homonymous quadrantanopsia involving the inferior quadrant. The term indicates a lesion in the parietal lobe.

Case 3

1. Fat embolism syndrome (FES).

The term fat embolism syndrome refers to a clinical entity that consists of pulmonary, central nervous system, and cutaneous manifestations.

Hypoxia, deteriorating mental status, and petechiae are the main diagnostic criteria; secondary diagnostic signs include tachycardia, fever, anemia, and thrombocytopenia.

Clinical diagnosis of cerebral fat embolism syndrome can be aided by noting the presence of respiratory failure, hypoxemia, and cutaneous petechiae. Neurological dysfunction varies from confusion to encephalopathy with coma and seizures.

2. Approximately 20-30% of the population have a patent foramen ovale; this may explain how fat emboli that pass through the pulmonary circulation end up with systemic manifestations of FES, particularly involving the brain and kidneys. As a result of the occluded cerebral vasculature, patients exhibit gross encephalopathy, localized cerebral edema, and white-matter changes.

3. Classification systems, including those devised by Schonfeld and Gurd, have been proposed to aid in the diagnosis of FES. Each system primarily relies on clinical assessment to establish the diagnosis.

Schonfeld assign the following scores for clinical findings associated with FES: petechiae=5; diffuse infiltrates evident on chest radiographs = 4; hypoxemia = 3; fever =1; tachycardia =1; tachypnea = 1; and confusion = 1. A cumulative score of more than 5 indicates FES.

The system for diagnosis proposed by Gurd has both major and minor criteria. The major criteria, which are similar to the criteria of Schonfeld, include petechial rash, respiratory insufficiency and changes in findings on chest radiographs, and cerebral involvement unrelated to head trauma. The minor criteria also overlap somewhat with the criteria of Schonfeld. In the Gurd system, minor criteria include tachycardia, fever, retinal changes, urinary changes, thrombocytopenia or anemia, elevated erythrocyte sedimentation rate, and fat globules in sputum. According to Gurd, diagnosis of FES requires the presence of 1 major criterion and 4 minor criteria.

4. Blood vessels injured by high plasma levels of free fatty acid, results in increased vascular permeability and consequently pulmonary edema.
5. The most effective prophylactic measure is to reduce long bone fractures as soon as possible after the injury.

There is no specific therapy for fat embolism syndrome; prevention, early diagnosis, and adequate symptomatic treatment are of paramount importance. Supportive care includes maintenance of adequate oxygenation and ventilation, stable hemodynamics, blood products as clinically indicated, hydration, prophylaxis of deep venous thrombosis and stress-related gastrointestinal bleeding, and nutrition. Medications, including steroids, heparin, alcohol, and dextran, have been found to be ineffective.

6. Magnetic resonance imaging of the brain revealed multiple hyperintense punctate lesions disseminated throughout the cerebral white matter on T₂-weighted axial images (Panel A) and a so-called starfield pattern on diffusion-weighted images (Panel B, C).

7.



The “starfield pattern” of scattered bright spots to be pathognomonic of acute cerebral microinfarcts; the signal intensity abnormalities presumably reflect foci of cytotoxic edema.

8. Small emboli, notably those composed of fat or air, occlude capillaries. Fat emboli originating from bone fractures are carried downstream through the cerebral vessels until the caliber of the emboli exceeds that of the blood vessels, at which point they lodge and block blood flow. The distal capillary endothelium becomes hypoxic and permeable, and petechiae develop, most commonly in the white matter.

Case 4

1. A halo pattern on a bedsheet produced by bloody otorrhea.
2. A secondary survey - this assessment is a complete examination of the patient from top to toe, both front and back.

1. Head and face.

- a. Posterior scalp lacerations / compound skull fractures.
- b. Pupils changes since primary survey.
- c. Visual deficits.

2. Neck.

- a. Injuries under the hard collar are not seen.
- b. In line immobilisation while the collar is off.

3. Chest.

- a. Clinical rib #s and sternal #s are missed.
 - i. Many do not show on the chest X-ray.
 - ii. They can compromise the patient.
 - iii. X-ray “proof” is not required.

4. Abdomen.

- a. Pain or tenderness or bruising requires further investigation.
- b. The inaccessible abdomen with appropriate mechanism requires investigation.
 - i. FAST or DPL in the unstable.
 - ii. CT in stable patients.
- c. Vaginal examination in female patients with pelvic fractures or vaginal bleeding.

In pregnancy this examination should be deferred to an obstetric specialist.

- d. A nasogastric tube is contraindicated in the presence of facial fractures (an orogastric tube should be inserted).
- e. A urinary catheter should only be inserted if there is no blood at the urethral meatus, no perineal bruising, and rectal examination is normal.

5. Back.

- a. Log roll takes 5 people, 3 body, one head, one examining.
- b. Inspection and palpation.
- c. Perform the rectal examination.

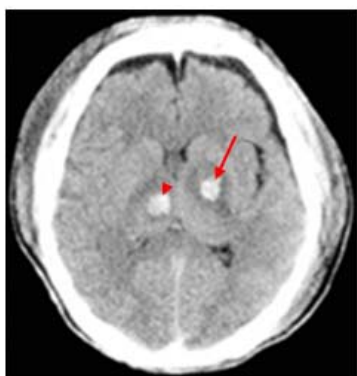
6. Extremities.

- a. Inspect and palpate each limb for tenderness, crepitation, or abnormal movement.
- b. If the patient is cooperative ask him or her to move the limbs in response to command in preference to passive movement in the first instance.
- c. Adequately splint any injuries.
- d. Reassess after splints, traction or manipulation.

7. Neurological examination.

- a. Repeat the Glasgow Coma Scale – record scores for E, V, and M as well as the total score.
- b. Re-evaluate the pupils.
- c. Look for any localizing / lateralizing signs.
- d. Look for signs of cord injury.

3. Diffuse axonal injury (DAI).



A CT scan of the head revealed hemorrhage of the posterior limb of the internal capsule (arrow) and hemorrhage of the thalamus (arrowhead). This clinical presentation and these CT findings are most consistent with diffuse axonal injury (DAI).

- Result from the disparate densities of the gray and white matter and the consequent difference in centripetal force associated with a rotational vector of injury.
- Most often occurs in high-speed motor vehicle accident.
- Present in 50% of all severe TBIs.

4. Corpus callosum and superior cerebellar peduncle.

5. Under microscope, axonal retraction balls, microglial stars, and degeneration of white matter fiber tracts can be seen. Fragmentation of axons and axonal swelling appear 24 to 48 hours after trauma. Axotomy may not be complete immediately after trauma.

The three levels of severity of DAI:

- Mild DAI: coma of 6 - to 24-hour duration.
- Moderate DAI: coma of more than 24 hours without decerebrate posturing.
- Severe DAI: coma of more than 24 hours with decerebrate posturing and flaccidity.

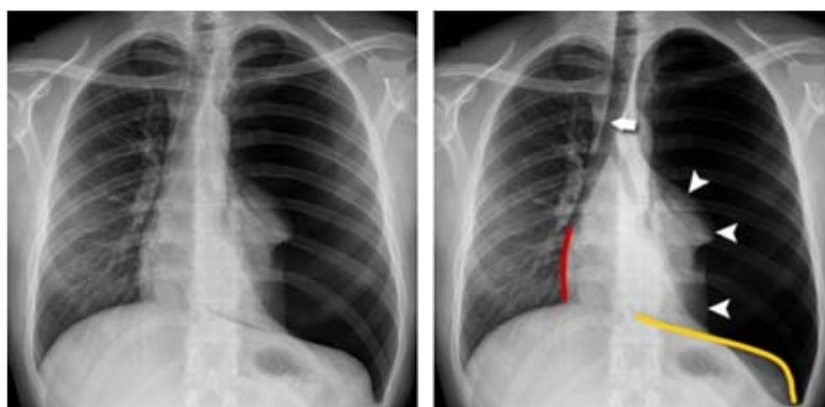
The mortality of severe DAI is 50%.

Case 5

4. You begin your head to toe secondary survey.

5-6. Computed tomography (CT) scan shows the left frontal hemorrhagic contusion and small right-sided subdural hematoma. Chest X-ray – the left-sided tension pneumothorax.

This is the one not to miss. If you cannot diagnose a tension pneumothorax at medical finals you won't find an examiner who will defend you.



The left hemithorax is black due to air in the pleural cavity.

The left lung is completely compressed (arrowheads).

The trachea is pushed to the right (arrow).

The heart is shifted to the contralateral side – note right heart border is pushed to the right (red line).

The left hemidiaphragm is depressed (orange line).

If you diagnose a tension pneumothorax clinically – do not request an X-ray, treat the patient!

7. Craniotomy.

8. Air embolism.

9. Packing the wound with wet sponges, lowering the patient's head, using jugular venous compression, rotating the patient's left side downward, aspirating from the venous line that is in the right atrium, and ventilating the patient while maintaining adequate blood pressure and heart rate.

Case 6

1. Despite this patient's obvious head injury and the possibility of an extra-axial hematoma, hemorrhage must be controlled as a priority and laparotomy performed emergently. Minimizing secondary brain injury from neuronal hypoxia is accomplished by ensuring adequate cerebral oxygenation and perfusion. Thus correction of shock is the first priority.

If the patient's neurological condition does not improve following arrest of hemorrhage and correction of shock, consideration may be given to performing blind burr holes in the operating room rather than transferring the patient to the CT scanner.

The correct answer is A. The patient should be transferred to the operating room for a laparotomy.

2. Prioritizing surgeries in trauma patients requiring surgery for both abdominal injuries and intracranial mass lesions is based on the initial hemodynamic status of the patient and on the response to fluid resuscitation. Stable patients with intraabdominal hemorrhage and severe head injury should undergo expeditious evaluation and treatment of their head injury, followed by more deliberate evaluation of their abdominal or thoracic injury. Those who are initially hypotensive but who stabilize after resuscitation should undergo a similar treatment plan. Patients who transiently respond but who again experience a drop in blood pressure should be moved rapidly to the operating room (OR) for treatment of their cavitory bleeding; evaluation of the head injury may proceed during treatment of the abdominal injury. Likewise, patients with persistent hypotension require immediate laparotomy, with intraoperative evaluation and possible treatment of the head injury. Avoiding secondary brain injury by preventing persistent hypotension and/or hypoxia is of primary concern. In many cases, these goals are best accomplished by surgical correction of ongoing abdominal bleeding. Effective communication between the trauma surgeon and neurosurgeon is critical to optimal outcome in these patients.

Case 7

The long spine board is more properly known as a rescue board. Its use is in the extrication of patients from entrapment situations. It may be used in the transfer of patients, although the scoop-stretcher and/or vacuum mattress are as safe and more comfortable.

The long spine board is not used to 'splint' the spine and offers no added protection once the patient is in hospital on a firm surface such as a hospital trolley or gurney. The spine board interferes with investigations such as X-rays and is extremely uncomfortable. Prolonged use (even as little as 2 hours) can lead to pressure ulceration.

Patients should be removed from the spine board as soon as possible - usually after the initial assessment and management of the primary survey. Obviously this should not take priority over life-threatening conditions. Full spinal immobilisation should be continued until the spine is cleared.

The correct answer is A. After the primary survey.

Case 8

The correct answer is E. Complete a trauma series X-ray.

A trauma series is a lateral C spine, chest and pelvis.

Review how to read a normal C-spine series.

I. 1. Cross table lateral view should be reviewed prior to removal of collar.

Need to see entire C1 to base of C7/top of T1. If not visualized you may either "pull" the patients shoulders down during the x-ray or a swimmers view may be obtained.

2. Smooth curve of 4 lines

- 1) Anterior vertebral
- 2) Posterior vertebral
- 3) Spinlaminar
- 4) Tips of spinous processes.

3. Shape of vertebral bodies

4. Normal facet joints

5. Spinous process fractures

6. Soft tissues swelling anterior to the vertebral bodies (<7mm at C8 and, 22mm at C6 is normal in adult).

II. The open mouth view should show the base of C1 and the entire dens of C2. The base should be properly aligned, and no fracture should be visible thru the dens.

III. The AP view displays the facets and the disc spaces. These should be aligned and evenly spaced.

Case 9

The correct answer is D. Defibrillation with 200 joules.

"You cannot avoid making mistakes unless you have experience.

You cannot gain experience without making mistakes."

Realising you are not invincible you go home to recuperate. Well done.

At home you read an article on stress relief for physicians.

Case 10

1. Acute SDH.
2. The magnitude of impact damage is much higher; there is always associated injury to underlying brain parenchyma and cerebral edema.
3. Up to 67% of patients with SDH have an underlying contusion.
4. The biochemical pattern of increased lactate and pyruvate and decreased partial pressure of oxygen in brain tissue (P_{btO_2}) may indicate evolving injury in the brain tissue that was previously compressed by the SDH.
5. Hyperdense crescentic mass of increased attenuation adjacent to inner table; usually on convexity but may be interhemispheric, along tentorium, or in posterior fossa.
6. Because of the low hemoglobin content, seen in up to 10%.
7. SDH is more diffuse, concave over brain surface, and often less dense (mixed with CSF).
8. Hyperdense: 1–3 days acute
Isodense: 4 days to 2–3 weeks subacute
Hypodense: >3 weeks chronic.
9. No, SDH can result from arterial ruptures (usually cortical arteries).
10. SDH resulting from arterial rupture are generally located in the temporoparietal region, and those caused by bridging vein rupture are in the frontoparietal parasagittal region.
11. No, venous SDH tends to have a homogeneous width, whereas arterial SDH tends to have a more pronounced thickening in the middle third.

12. When the midline shift exceeds the hematoma thickness; the prognosis has been found to be poorer. Also termed shift out of proportion.

13. • Early: within 4 hours of injury.
• Late: after 4 hours of injury.

14. In some cases, brainstem shift away from the mass lesion may produce compression of the opposite cerebral peduncle against the tentorium, which results in hemiparesis on the same side as the lesion, a false localizing sign.

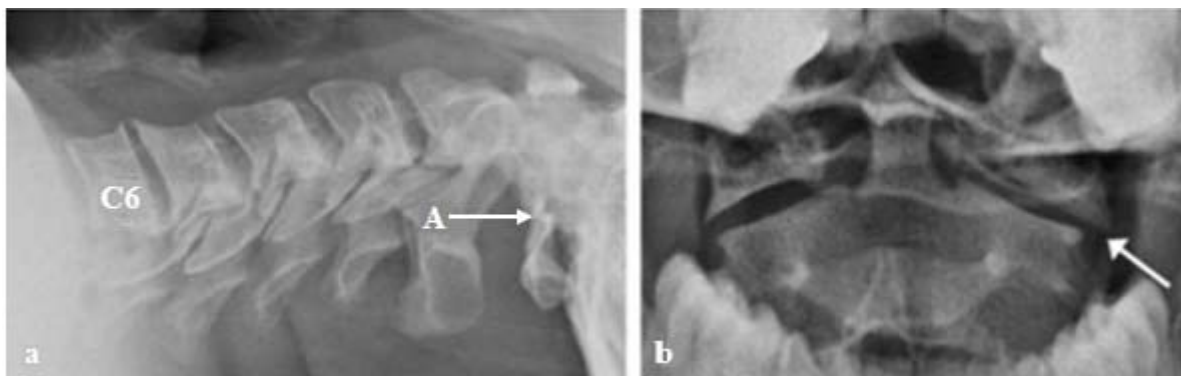
Case 11

1. The Canadian Cervical Spine Rule is a widely adopted and validated instrument to determine whether a neurologically intact patient who has sustained blunt trauma with a suspected cervical spine injury should have cervical spine imaging. The presence of any of the following major factors mandates a three-view radiograph of the cervical spine:

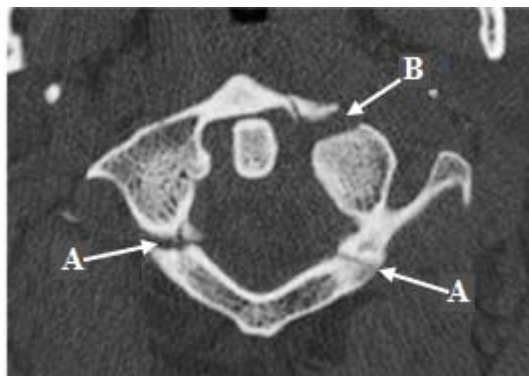- Age > 65 years,
- Paresthesia in extremities,
- Dangerous mechanism (including fall from > 1m or five stairs, RTA > 100km/h or involving roll-over or ejection from a vehicle, bicycle, or recreational vehicle accident).

A patient also qualifies for imaging if they meet one of several minor criteria or if they cannot actively rotate the neck more than 45° to either side. This patient qualifies for imaging on the basis of a dangerous mechanism of injury.

2. A lateral cervical spine X-ray should provide adequate views up to the C7/T1 junction. This is an inadequate film as the last visible vertebra is C6. There is a fracture in the posterior ring of the atlas (Panel a, A). There is separation of the lateral masses on the PEG view, producing an 'overhang' of C1 on C2 (white arrow in Panel b: the edge of C1 is not in line with the edge of C2). This is abnormal, and may indicate disruption and instability of the atlanto-axial complex. This patient requires a CT scan of the cervical spine to define these injuries and to enable viewing of the entire cervical spine.



3.



(a) There is a burst fracture of the atlas (Jefferson's fracture) involving the posterior laminae bilaterally (A) and the left anterior arch (B).

(b) This type of injury is associated with axial loading, suggesting that the patient may have landed on his head.

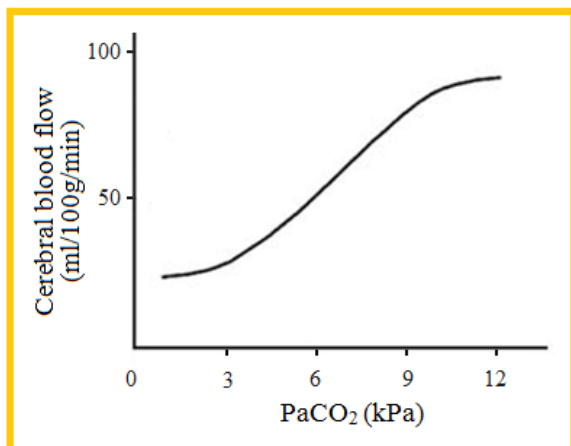
(c) A fracture in the cervical spine is associated with an increased incidence of fractures elsewhere in the spine. Therefore the patient should remain supine and log-rolled until the rest of the spine is imaged and fractures excluded. In most cases plain X-rays of the thoracic and lumbar spine will adequately serve this purpose.

4. The management of C1 fractures depends on the integrity of the transverse ligament. This can be assessed by MRI, or functional stability can be assessed by flexion–extension views. If the transverse ligament is intact, the treatment is cervical immobilization with a cervical collar or halo vest. If the transverse ligament is disrupted, the treatment is with a halo vest or internal occiput to C2 fixation. In this patient the transverse ligament was intact and a Miami J collar was prescribed for 12 weeks with CT scans scheduled at 6 weeks and 12 weeks to assess healing.

5. A cervical collar promotes healing by immobilizing the cervical spine in patients with stable fractures. The Miami J collar limits flexion and extension by 55–75%, rotation by 70%, and lateral bending by 60%. In

general, the collar needs to be worn at all times, including when bathing and going to sleep, although in certain circumstances the clinician may allow exceptions depending on the type of injury. The collar has removable internal soft pads that can be replaced after bathing.

Case 12



1. Cerebral blood flow is dependent on the PaCO₂ as carbon dioxide dilates the cerebral vessels. This increase is accompanied by an increase in cerebral blood volume and therefore a rise in intracranial pressure. Reduction of PaCO₂ levels by increasing minute ventilation allows some control of intracranial pressure.

However hyperventilation will lead to hypocapnia (below PaCO₂ of 4kPa – 30 mmHg), and with it cerebral vasoconstriction. This can lead to hypoxia and cerebral ischemia and should be avoided. The primary goal of the management of traumatic brain injury is prevention of secondary neuronal damage by maintaining oxygenation and perfusion.

The correct answer is A. Increase ventilation to achieve normocapnia.

2. The correct answer is D. ↑ BP, ↓ HR, ↓ CPP

The important relationship between cerebral perfusion pressure (CPP), mean arterial blood pressure (MAP) and intracranial pressure (ICP) is as follows: $CPP = MAP - ICP$. It stems from the fact that the adult brain is enclosed in a rigid, incompressible box, with the result that the volume inside it must remain constant (Monro–Kelly doctrine). A rise in intracranial pressure therefore decreases cerebral perfusion pressure (and hence cerebral blood flow). In raised intracranial pressure, as the brainstem becomes compressed, local neuronal activity causes a rise in sympathetic vasomotor drive and thus a rise in blood pressure. This is known as the Cushing's reflex. This elevated blood pressure evokes a bradycardia via the baroreceptor reflex. The Cushing's reflex helps to maintain cerebral blood flow and protect the vital centres of the brain from loss of nutrition if the intracranial pressure rises high enough to compress the cerebral arteries.

Case 13

1. CT scan of the brain reveals bilateral subdural hematomas which are mainly chronic with a very small subacute component on the right side. The right subdural hematoma is close to 1.5 cm in thickness. The left subdural hematoma is ~1.3 cm in thickness. They are both mainly along the convexity in the frontal and somewhat parietal area. There is some diffuse brain atrophy in both frontal lobes consistent with advanced Alzheimer's disease. There also appears to be no midline shift, no obvious mass effect, and no edema. The basal cisterns are wide open. There might be some effacement in the sulci along the cortical surface in the frontal lobes.

2. Elderly, alcoholism, seizures, CSF shunt, coagulopathies, and patient at risk for falls.

3. Most cases start out as an acute SDH evoking an inflammatory response, fibroblasts invade the clot, membranes are formed on the inner (brain) and outer (dura) surfaces, followed by growth of neocapillaries and liquefaction of blood.

4. 3 weeks following initial presence of the blood.

5. Patients may deny history of trauma, which often is mild and often not remembered. Pseudodementia, gait ataxia, focal weakness, headaches, and stroke-like symptoms are some of the most frequent forms of presentation; less frequently seizure or meningismus.

6. In patients with coagulation anomalies or medicated with aspirin, clopidogrel, warfarin, or similar medication, reversal of anticoagulation with vitamin K and fresh frozen plasma is paramount. Surgery should be performed on symptomatic lesions or CSH with maximum thickness >1 cm with >5 mm of midline shift.

7.

- Its frequent recurrence.
- The lack of consensus regarding surgical techniques, perioperative management, and medical approach to nonsurgical cases.

8.

- Two burr holes and irrigating through and through
- Single large burr hole with irrigation and aspiration
- Single large burr hole drainage and placement of a subdural drain
- Twist drill craniostomy
- Formal craniotomy with membranectomy; DO NOT attempt to remove the deep membrane adherent to the pia.
- Use closed-system drainage.

- Keep the patient on bedrest with head of bed (HOB) flat (for 24 hours, according to most authors).

9.

- Use copious irrigation.
- Use closed-system drainage.
- Use bipolar coagulation of the edge of the dura and subdural membrane back to the full width of the bony opening.
- Place a piece of Gelfoam over the opening to help prevent flesh blood oozing into the opening.
- Use the suggested postoperative posture: recent studies indicate that the supine position may decrease recurrence.

10. Patients who have high subdural fluid pressure tend to have more rapid brain expansion and clinical improvement.

11. Clinical improvement does not require complete resolution of the fluid collection on CT. DO NOT treat persistent fluid collection based only on CT.

12.

- Implantation of an Ommaya reservoir in the subdural cavity with subsequent serial aspiration.
- Shunting of the subdural space.

Case 14

The correct answer is A. Sleep-wake cycles.

A persistent vegetative state (PVS) is a vegetative state present for 1 month after brain injury. The vegetative state is characterized by the absence of awareness of self or the environment. The patient in a PVS has preserved sleep-wake cycles but has no behavioral response to any stimuli and has no language comprehension or expression. Patients are incontinent and require skilled nursing care. Unlike patients who are brain dead, cranial nerve reflexes are variably preserved in a vegetative state.

Case 15

The correct answer is B. Fluid resuscitation with 0.9% NaCl.

The main cause of the agitation in this ventilated patient is hyponatremia. Hyponatremia is a common complication post brain injury and it is essential to find out the underlying cause in order to guide further treatment. The two most

important differential diagnoses in a patient with a brain injury are syndrome of inappropriate ADH (SIADH) and cerebral salt-wasting syndrome (CSWS). Both are characterized by low serum sodium and raised urinary sodium and urine osmolality, but there are some important distinctions between the two. The patient with CSWS produces large volumes of urine which results in plasma volume depletion. They will appear dehydrated and show signs of hypovolemia (which may explain the tachycardia and hypotension in this case). In SIADH, low volumes of concentrated urine are produced, and patients tend to be euvolemic. As a result, the management of the two is extremely different. Whilst SIADH is treated with fluid restriction and demeclocycline 600–1200mg/day to inhibit the renal response of ADH, CSWS requires restoration of plasma volume and sodium levels. This can be initially done with 0.9% NaCl, although hypertonic saline can be considered. Fludrocortisone 0.1–0.4mg/day is given in resistant cases for postural hypotension. Desmopressin is synthetic vasopressin and is used in the treatment of cranial diabetes insipidus and von Willebrand's disease.