

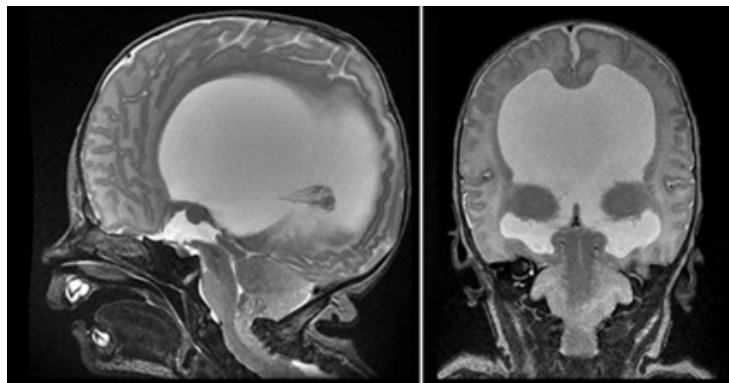
EANS/UEMS European examination in neurosurgery

Variants of questions with answers (compilation - Vyacheslav S. Botev,
Department of Neurosurgery, M.Gorky Donetsk National Medical University)

CASE HISTORIES IN PEDIATRIC NEUROSURGERY

Case 1

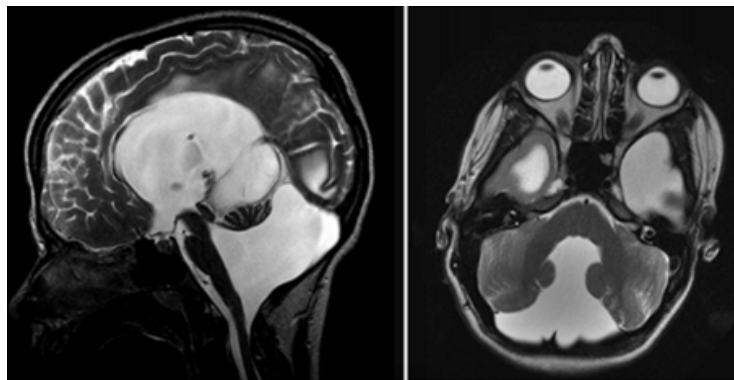
Child with a prior history of myelomeningocele repair, now with vomiting.



1. Summarize all visible imaging findings
2. What is the diagnosis?
3. This condition is usually associated with what problem?
4. Which fruits are used to describe the findings on prenatal ultrasound?

Case 2

A 6-year-old boy presents with headaches and loss of balance.



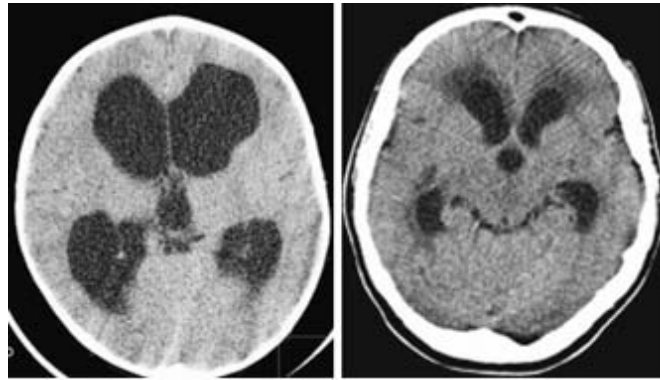
1. What are the presented imaging findings?
2. What is your diagnosis?

3. What are the differential diagnoses of cystic posterior fossa lesions?
4. What additional lesions may occur with the presented syndrome?

Case 3

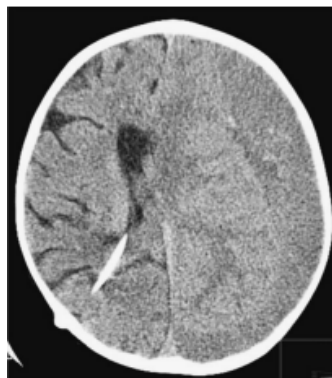A 6-month-old boy presents via the pediatricians with progressively enlarging head circumference. His head now measures 51.5cm, which makes it far above the 95th centile (5th to 95th centile range 41.5–46cm). There is no medical history of note; he was born by ventouse delivery at 38 weeks and is developmentally normal. Examination finds that there is a bulging fontanelle but no loss of upgaze, and the boy seems alert and normal apart from his head, which is clearly enlarged.

1. A CT scan is done. Comment on the findings and the management options.



2. Would you have any concerns about shunting this boy over and above the usual concerns about VP shunt placement in a child?

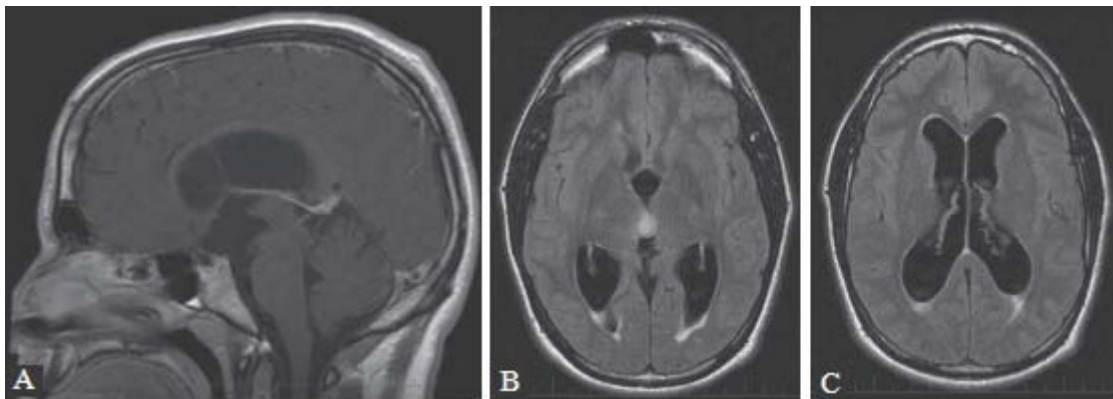
A VP shunt is placed with a medium–low pressure (70mmH₂O) valve. The boy is discharged 2 days later, but is taken to his GP after 3 weeks with progressive irritability, fluctuating consciousness, and vomiting. His GP suspects that the shunt is blocked and refers him directly for a CT scan.



3. What does the CT scan show and how would you treat the patient?
4. How can you prevent shunt infection?

Case 4

A 15-year-old adolescent boy presents with a long history of intermittent syncopal episodes. He was initially investigated at age 10 by a neurologist with normal cranial imaging, normal electroencephalogram (EEG), and normal physical examination. Similar episodes recurred at age 15 and although his neurologic examination remained normal, magnetic resonance imaging (MRI) was performed as part of further investigations, and was significantly different from the prior computed tomography (CT) scan. Representative images are presented below.



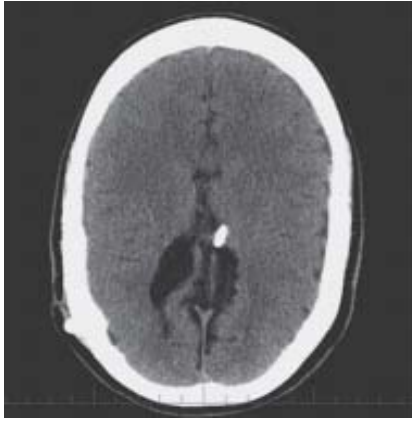1. Describe the findings on the imaging study.
2. What advice would you give the patient in terms of management?
3. What would be the basis for intervention in this patient?
4. Describe possible surgical interventions for the management of this patient.

The patient underwent a successful endoscopic third ventriculostomy (ETV) and biopsy of the third ventricular mass. The pathology was consistent with juvenile pilocytic astrocytoma.

5. Describe the risks associated with the above procedure.
6. Are there any specific technical considerations for the procedure?
7. What is the long-term prognosis for this patient?
8. What is your management strategy for the patient given the above information?

Case 5

A 13-year-old girl with a history of myelomeningocele repaired at birth and with a ventriculoperitoneal (VP) shunted inserted shortly after birth presents with headache. She has a history of only one previous shunt revision. She is stable neurologically with a L4/L5 clinical level (both motor and sensory deficits), but presents with a new onset of disabling headaches over the past several months.



Computed tomography (CT) scan shown on the left is no different from the routine scan done 1 year previously when she was completely asymptomatic.

1. What is the differential diagnosis?
2. What is the next possible step in the workup of this patient?

Shunt revision is performed, and at the time of surgery the distal and proximal catheters are changed due to “sluggish” flow. She is relieved of her headaches for a few hours, but the symptoms return shortly thereafter.

3. What are the diagnostic possibilities now?
4. What is the next step in her management?

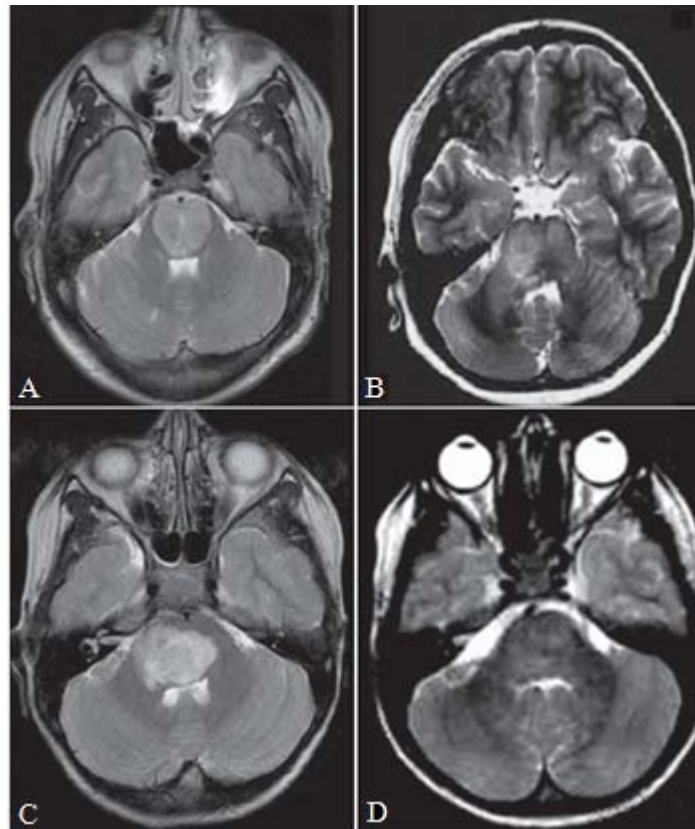
CT scan remains unchanged; nuclear medicine shuntogram shows good flow.

5. What are other potential investigations?

Intracranial pressure (ICP) monitoring shows readings generally between 5 and 15 mm Hg depending on her position with no single reading higher than 20 mm Hg, and no reading lower than -5 mm Hg.

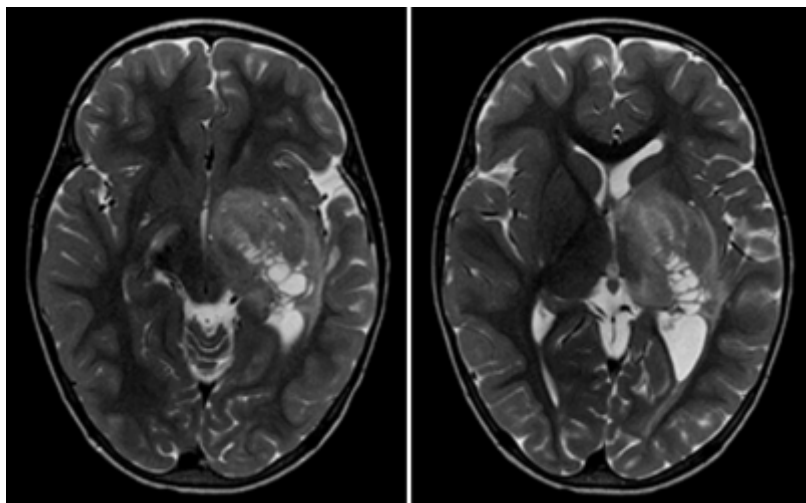
6. Describe the different types of syndromes associated with headaches and stable ventricle size on CT can and outline management strategies for each.

Case 6



1. What are the four categories of the pathologic condition shown in these four different children?
2. What are the four diagnoses?
3. Place these children in order according to their prognosis, from good to poor.
4. Which child or children will most likely display additional lesions in the brain?

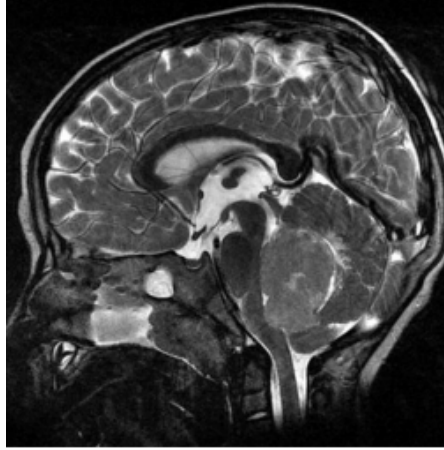
Case 7



1. What are the imaging findings in this 12-year-old girl with dystonia?
2. What is the diagnosis?

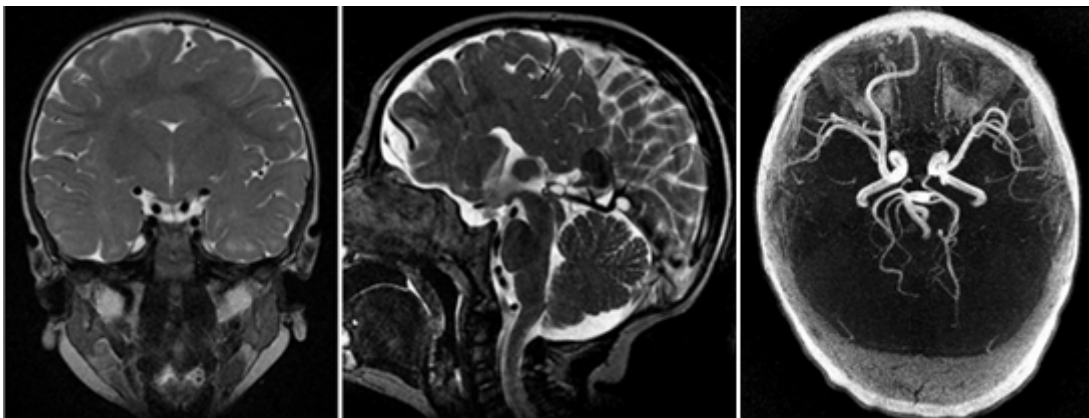
3. What are the most likely histologic diagnosis and grade?
4. What are the most likely findings on proton magnetic resonance spectroscopy ($^1\text{H-MRS}$) measured within the lesion?

Case 8



1. What are the imaging findings in this 15-month-old boy?
2. What is the most likely diagnosis?
3. What are the four most frequent tumors in the posterior fossa in children?
4. What is one of the most significant prognostic factors for long-term survival?

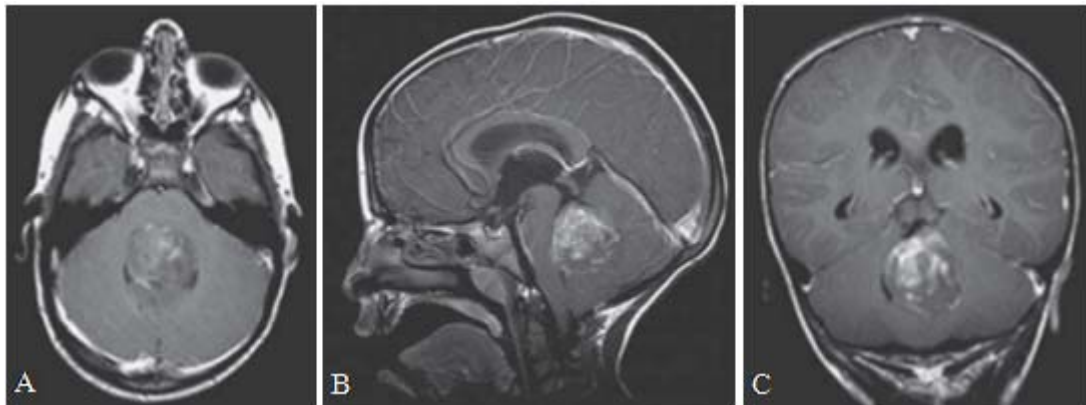
Case 9



1. What are the imaging findings on magnetic resonance imaging (MRI) and magnetic resonance angiography?
2. What is seen on the fractional anisotropy map?
3. What is the diagnosis?
4. To which group of anomalies does this malformation belong?

Case 10

A 6-year-old boy presented with a history of clumsiness, slurred speech, and headache for the past 3 months. Clinical examination revealed a broad-based, ataxic gait with poor coordination. Computed tomography (CT) scan of the head without contrast showed a hyperdense, midline posterior fossa mass with minimal ventricular enlargement. Magnetic resonance imaging (MRI) scan of the brain is shown below.

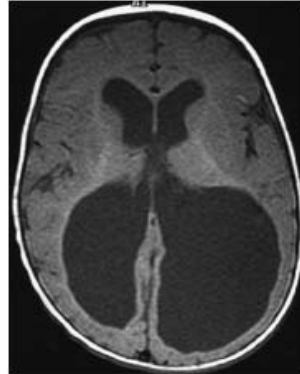


T1-weighted magnetic resonance image (with gadolinium contrast) of the brain. (A) Axial, (B) sagittal, and (C) coronal views showing a large, contrast-enhancing 4th ventricular tumor.

1. What is your differential diagnosis based on clinical and imaging findings?
2. What other imaging study would you recommend?
3. Where do medulloblastomas arise and what are the different histopathologic subtypes?
4. What is the definitive management of this lesion? What is the role of surgery?
5. What surgical approaches can be used for resection of this tumor?
6. Is adjuvant treatment indicated, and if so, what would you recommend?
7. If you recommend radiation, what is the dose of radiation you would use?
8. How often is ventriculoperitoneal shunt required in patients with medulloblastomas? What can be a shunt-related complication in these patients?
9. Describe a grading system used that affects prognosis in medulloblastoma patients.

Case 11

An infant born at 30 weeks was diagnosed with an intraventricular hemorrhage at 23 weeks by in utero ultrasound. He has a normal head circumference at birth. Serial head circumference measurements are stable for the first 3 months and then begin to climb over the 95th percentile for his age. Brain MRI (axial T1-weighted image) is shown .

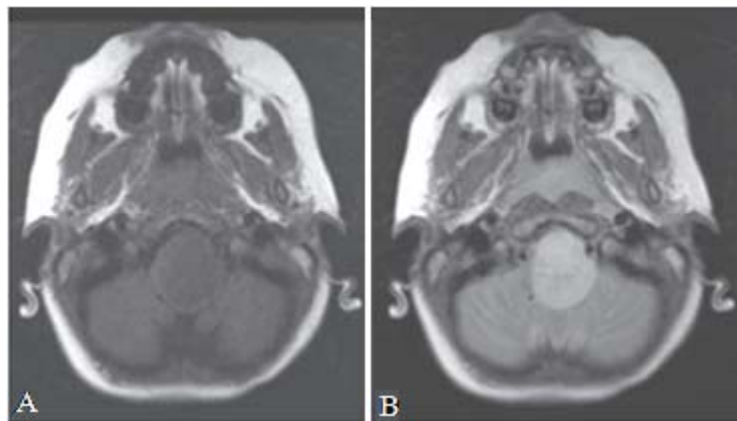


1. What does the MRI show?
2. Is it likely to be communicating or non-communicating?
3. What features on the MRI demonstrate elevated ICP?
4. What clinical symptoms and signs would confirm your diagnosis?
5. What is the best treatment for this patient?

Case 12

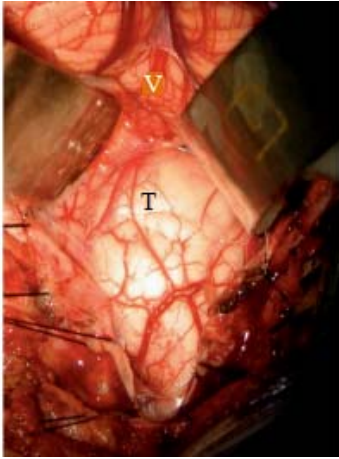
A 4-year-old boy presents to the emergency room sent by his pediatrician for head tilt and nystagmus. He also has frequent headaches. Examination shows only nystagmus and head tilt toward the left side. There are no other cranial nerve findings, and the remainder of the neurologic exam is within normal limits. Magnetic resonance imaging (MRI) scan was obtained.

1. Interpret the MRI scan.



Magnetic resonance imaging scan at the level of the medulla. (A) Axial cuts T1-weighted and (B) T2-weighted.

2. Give a differential diagnosis.
3. What studies do you order?
4. What is the next step in the patient's management?
5. Describe approaches to intraaxial brainstem tumors, surgical principles, and adjuncts. The patient was taken to surgery. A tumor was expanding the medulla oblongata, deforming the anatomy, and displacing the midline:



Intraoperative image of the floor of the 4th ventricle showing entry site to the tumor (T) and cerebellar vermis (V).

Using neuronavigation, the area closest to the surface was the point used for entry. On the frozen section, the patient's specimen confirmed a diagnosis of juvenile pilocytic astrocytoma.

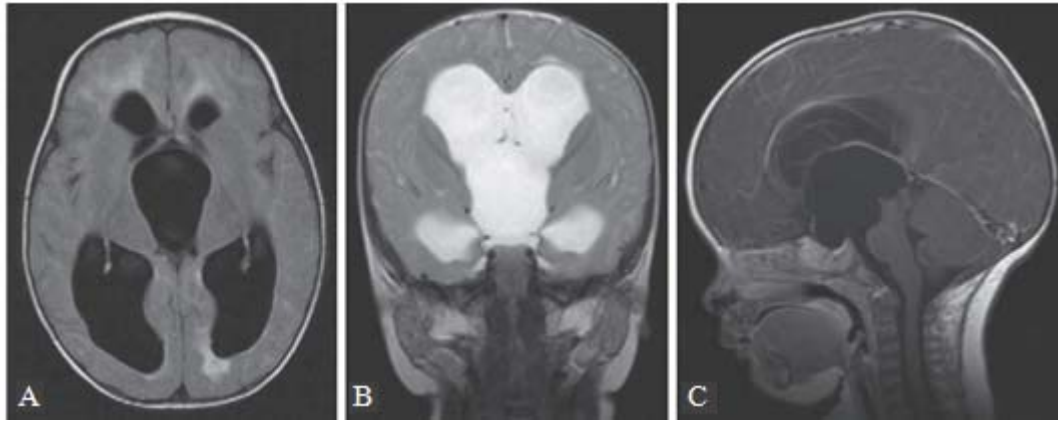
6. What are the treatment alternatives at this age?
7. What do you tell the family with respect to prognosis?

Case 13

An 8-month-old child with normal prenatal, birth, and early infancy health history presented with increase head circumference and delayed milestones achievement. Her parents noticed that over several weeks she had lots the ability to crawl and the ability to sit unassisted. Examination revealed a head circumference at the 98 th percentile compared with the 50th percentile 2 months ago and a bulging fontanel, as well as impaired upwards gaze.

1. What are the diagnostic possibilities in this child?
2. What are the appropriate investigations?

A magnetic resonance imaging (MRI) of her brain was performed urgently; the scan is shown below.



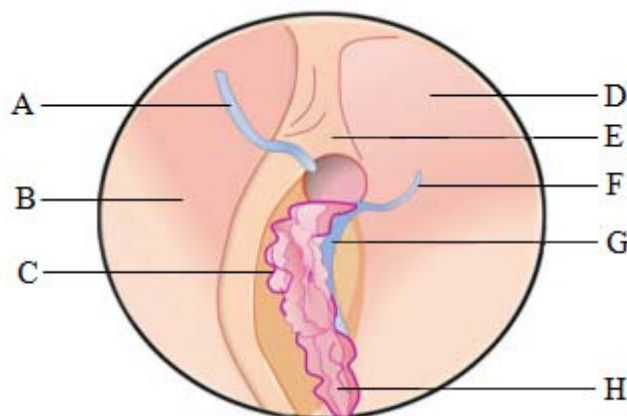
Magnetic resonance imaging scan of the brain with (A) axial fluid-attenuated inversion-recovery, (B) coronal T2-weighted, and (C) sagittal T1-weighted images with contrast.

3. What are the findings on the MRI and what is the differential diagnosis?
4. What are the options for treatment of this lesion?
5. Explain what you would tell the parents in terms of risks for this procedure.
6. What is the chance of success of this procedure?
7. What would be the option if the initial procedure fails?

Case 14

Endoscopy of a right lateral ventricle.

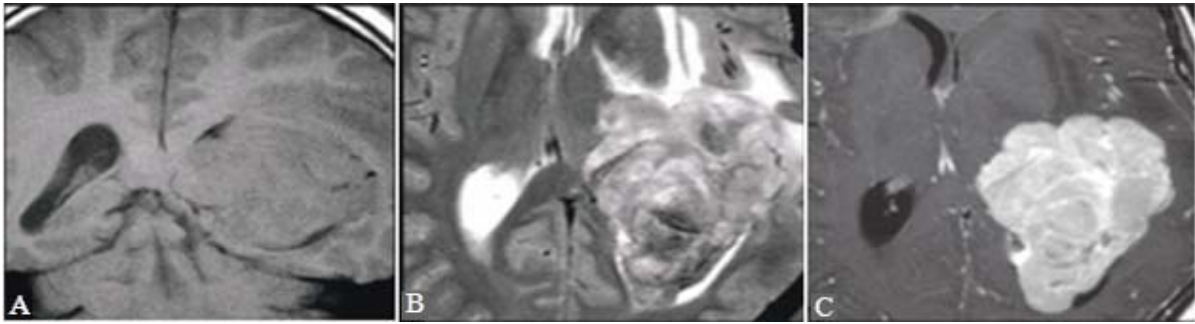
Directions: Figure below depicts an endoscopic approach to the third ventricle. Match the following anatomic structures to the corresponding letterhead, using each answer once, more than once, or not at all.



1. Thalamostriate vein
2. Septal vein
3. Choroid plexus
4. Anterior caudate vein
5. Fornix
6. Caudate nucleus
7. Septum pellucidum
8. Choroid fissure

Case 15

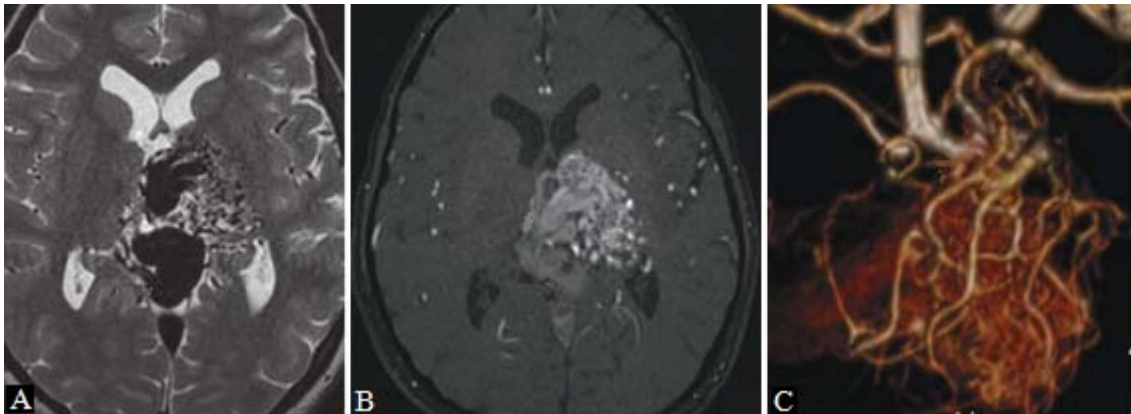
A 4-year-old boy with intractable headache and visual disturbance.



1. What does the MRI show?
2. What is the differential diagnosis?
3. What is the most likely diagnosis?
4. Is preoperative craniospinal imaging necessary in this lesion?
5. What the treating physician needs to know?

Case 16

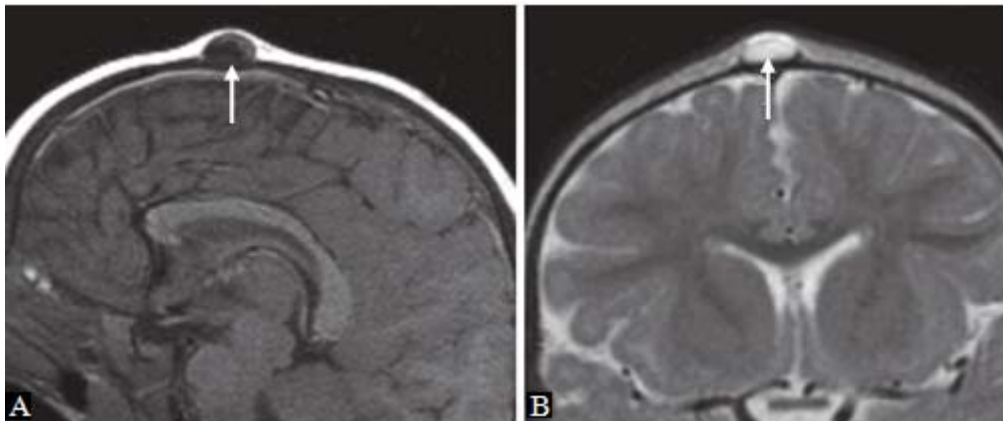
A 13-year-old girl with dystonia and contractions of the right hand.



1. Describe the findings on the imaging study.
2. What is the differential diagnosis?
3. What is your diagnosis?
4. What are the complications of AVM?
5. What the treating physician needs to know?

Case 17

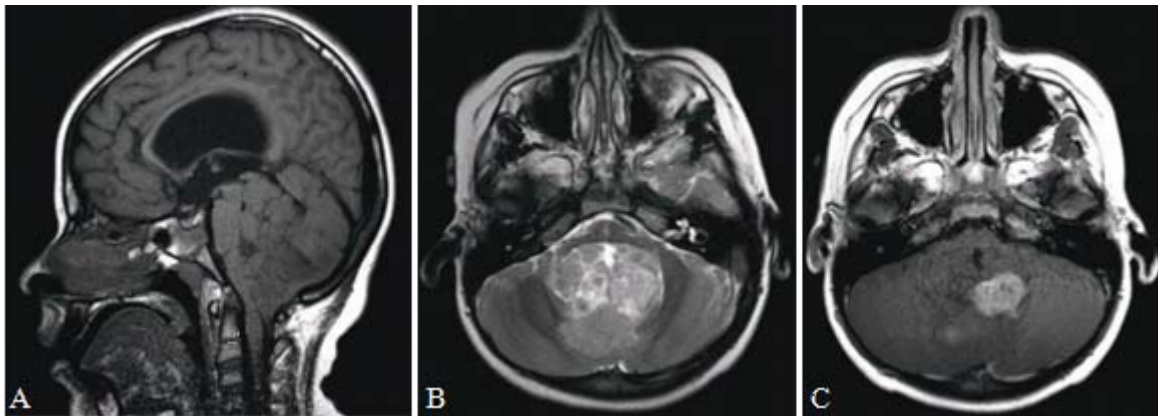
A 12-month-old boy with a nodule at the site of the anterior fontanel.



1. What does the MRI show?
2. What is the differential diagnosis?
3. What is the most likely diagnosis?
4. Can a dermoid be differentiated from an epidermoid by imaging?
5. What the treating physician needs to know?

Case 18

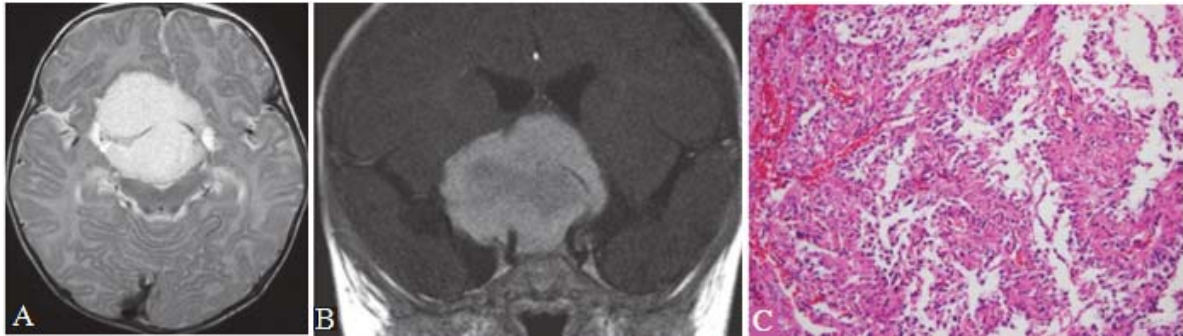
A 10-year-old boy with headache.



1. Summarize all visible imaging findings.
2. What is the differential diagnosis?
3. What is your diagnosis?
4. Where, precisely, is the layer of cells from which an ependymoma arises?
5. What the treating physician needs to know?

Case 19

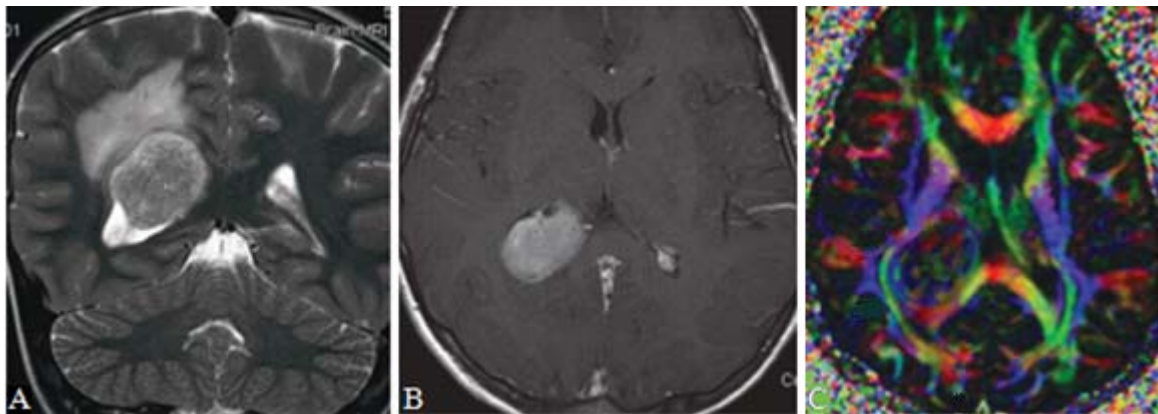
A 4-month-old child with failure to thrive for the last 2 weeks. MRI and postoperative photomicrograph of the lesion are shown.



1. Describe the findings on the imaging study.
2. What is the differential diagnosis?
3. What is your diagnosis?
4. Do pilomyxoid astrocytoma (PMA) need more aggressive therapy?
5. What the treating physician needs to know?

Case 20

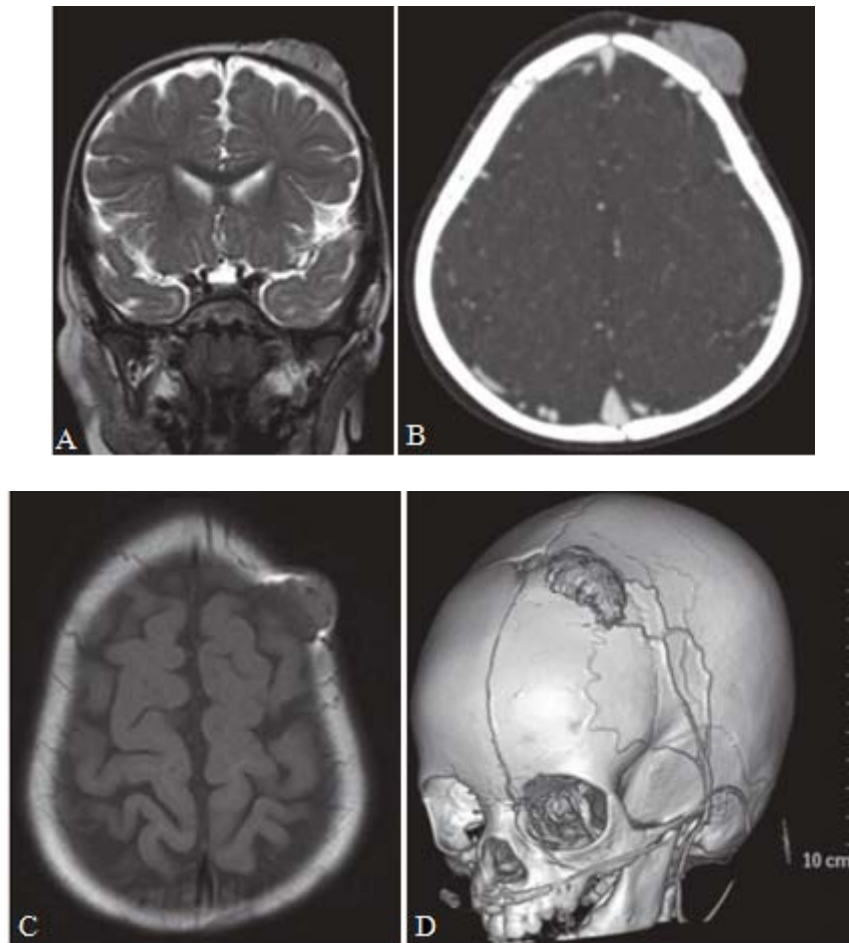
An 11-year-old girl diagnosed with neurofibromatosis type 2 (NF2) has a growing intraventricular mass.



1. What are the imaging findings?
2. What is the differential diagnosis?
3. What is the most likely diagnosis?
4. Apart from meningioma, what other intracranial tumors occur in NF2?
5. What the treating physician needs to know?

Case 21

An 1-year-old child with developing head mass.



1. Describe the findings on the imaging study.
2. What is the differential diagnosis?
3. What is the most likely diagnosis?
4. How many clinically distinct “hemangiomas” are there in the body?
5. What the treating physician needs to know?

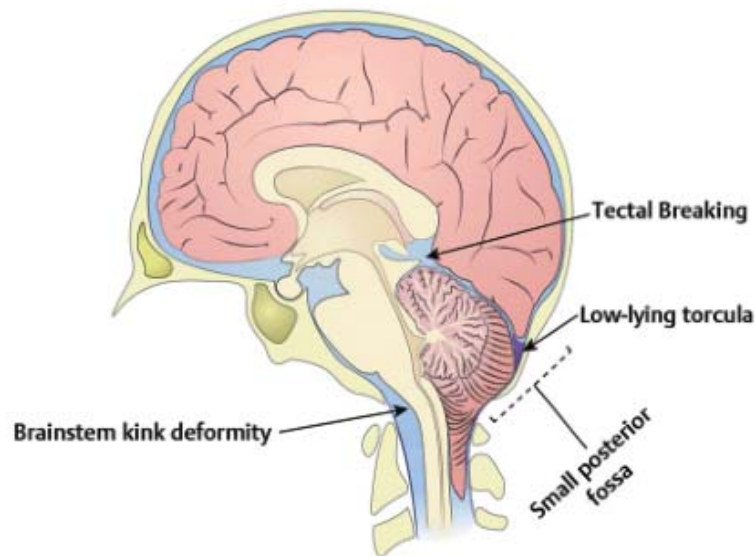
Answers

Case 1

Diagnosis: Arnold-Chiari II Malformation.

1. Small posterior fossa, embracement of the brainstem, tectal beaking, tonsillar herniation, kinking of the cervical cord, compressed brainstem, colpocephaly, hypoplastic falx cerebelli, corpus callosum dysgenesis or agenesis, large massa intermedia, and occipital stenogyria.
2. Arnold-Chiari II malformation.
3. Open (nonskin covered) myelomeningocele.
4. Lemon-shaped calvarium and banana –shaped cerebellum.

Comment



The Arnold-Chiari II malformation is named after Dr. Julius Arnold and Dr. Hans Chiari. This is a complex malformation that primarily involves the posterior fossa, which is too small. An extensive, complex combination of supra- and infratentorial malformations result from this condition. Arnold-Chiari II malformation is present in all patients with an open, nonskin-covered myelomeningocele.

Magnetic resonance imaging is the best imaging modality to summarize all findings. Imaging findings include the small posterior fossa, a squeezed cerebellum and brainstem (resulting in a compression of the brainstem against the clivus), herniation of the cerebellar tonsils into the upper cervical spinal canal with kinking of the spinal cord, embracement of the brainstem by the cerebellar hemispheres, deformity (beaking) of the tectal plate, ascending herniation of the superior cerebellum through the tentorium cerebelli,

supratentorial hydrocephalus with colpocephaly, thinning and/or dysgenesis of the corpus callosum, large massa intermedia, and a fenestrated hypoplastic falx cerebri with interdigitation of the mesial gyri. The occipital cortex may mimic polymicrogyria.

Arnold-Chiari II malformation may be associated with syringohydromyelia in 50% to 70% of children. An increased incidence of diastematomyelia also exists. Diagnosis is frequently made during the prenatal screening. Increased alpha-fetoprotein is highly suggestive of an open myelomeningocele. On prenatal ultrasound the downward displacement of the flattened and elongated cerebellum mimics a banana, whereas the inward depression of the frontal bones mimics a lemon. Most children require a ventriculoperitoneal shunt to treat the hydrocephalus. Prognosis is variable and depends on the degree of hydrocephalus and associated malformations.

Case 2

Diagnosis: Dandy-Walker Malformation.

1. Cystic dilation of the fourth ventricle, hypoplastic elevated and rotated upper vermis, enlarge posterior fossa, hydrocephalus, and keyhole appearance of the fourth ventricle.
2. Dandy -Walker malformation (DWM).
3. Blake pouch, retrocerebellar arachnoid cyst, and mega cisterna magna .
4. Hydrocephalus, corpus callosum dysgenesis, migrational abnormalities (gray matter heterotopias, polymicrogyria, schizencephaly), occipital encephaloceles, and hydromyelia of the cervical cord .

Comment

DWM is named after the neurosurgeon Walter E. Dandy and the neurologist Arthur E. Walker. A DWM is characterized by a cystic dilation of the fourth ventricle because of defective development of the anterior and posterior velum medullare. The vermis is hypoplastic or may be completely absent.

A spectrum of DWM is known, and depending on the degree of malformation, different names are used. The more extensive anomalies are known as classic DWM or DW-variant; the less severe forms are known as Blake pouch cyst or mega cisterna magna. It should be kept in mind that not every cystic lesion within the posterior fossa is a DWM.

Differential diagnosis includes a retrocerebellar cyst. In addition, DWM should be differentiated from a cerebellar hypoplasia or brainstem malformation, as well as from an infarcted cerebellum. The classic DWM is characterized by a cystic dilation of the fourth ventricle, usually with an absent choroid plexus, an upward rotated hypoplastic vermis, a large posterior fossa with elevation of the torcular herophili, and elevated straight sinus. The tentorium cerebelli may be hypoplastic. Frequently a supratentorial hydrocephalus occurs. Hydrocephalus does not have to be present at birth. In 60% of patients, associated findings are seen that include hydrocephalus, corpus callosum dysgenesis, migrational abnormalities (gray matter heterotopias, polymicrogyria, schizencephaly), occipital encephaloceles, and hydromyelia of the cervical cord.

A majority of children will have a mental retardation. In addition, DWM is reported to be associated with cardiac anomalies and polydactyly. Magnetic resonance imaging (MRI) easily makes the diagnosis. Differential diagnosis from a Blake pouch cyst and a mega cisterna magna may be challenging. A key feature is the identification of an intact vermis. In addition, DWM should be differentiated from acquired injuries of the cerebellum and vermis. Prognosis may differ significantly. Frequently, a DWM is diagnosed intrauterine by prenatal ultrasound examination. The fourth ventricle may have a typical keyhole appearance.

Case 3

1. The CT shows grossly dilated ventricles. The most likely cause is aqueduct stenosis or another congenital malformation. However, an MRI does not show aqueduct stenosis, and therefore the diagnosis is considered to be 'idiopathic' hydrocephalus.

The child requires treatment of the hydrocephalus to avoid developmental delay. Given his age (under 1 year) and the lack of obstruction to CSF circulation (e.g. tumor, aqueduct stenosis) as a cause of the hydrocephalus, treatment should be a ventriculoperitoneal shunt rather than endoscopic third ventriculostomy, which, although preferable as a successful treatment for hydrocephalus, has lowest success rates in children under 1 year old and patients with communicating hydrocephalus.

2. The degree of the ventricular dilation raises concern about draining CSF too rapidly. The skull will not collapse as it would in a neonate, and hence there is concern about the cortex falling away from the skull because of the loss of CSF volume. In this situation the child may be drowsy for some time post surgery or

may develop subdural effusions. Strategies to minimize this include programmable shunt valves or prolonged bed rest after shunt placement to prevent over-drainage due to siphoning effects of the shunt tubing.

3. The CT does not suggest that the shunt is blocked as the ventricles are small. Rather, it suggests that the shunt is working too well; the ventricles are now far smaller and there is CSF overlying the cortex on the right side. However, there is a large slightly hypodense (compared with brain) collection overlying the left cerebral hemisphere with midline shift to the right due to a subdural hematoma. The shunt catheter is seen within the occipital horn of the right lateral ventricle. The subdural hematoma has arisen because of the lower intracranial pressure and collapse of the brain due to over-drainage of ventricular CSF. Simply draining the subdural hematoma will invite it to recur. There must also be a change in the CSF drainage process. This will involve changing the function of the shunt. There are three options, in addition to draining the hematoma.

1. Tie off the shunt temporarily with a view to untying it after the subdural hematoma has resolved clinically and radiologically.
2. Change the valve for one with a higher opening pressure.
3. Change the valve for one with variable opening pressure.

Option 3 is probably preferable for this boy. The brain can be encouraged to reexpand by a period of higher CSF pressure and after a few weeks, when another CT scan has confirmed that the subdural collection has gone, the shunt pressure can be turned down in small graduated steps. It is hoped that any recurrence of the subdural hematoma will be small enough to be managed non-operatively by cautious reprogramming of the valve.

4. 1. Double glove use.
2. Don't touch the catheter when inserting it in the abdomen (use bayonnetted forceps).
3. Don't let CSF leak (good closure!).
4. Do it quickly! (longer intraoperative times are associated with higher infection rates).

Case 4

1. The MRI demonstrates ventriculomegaly at the level of the lateral ventricles with some transependymal edema. There is also an apparent mass in the

posterior part of the 3rd ventricle and tegmentum of the brainstem.

2. Management strategies for this patient can be divided into observational and interventional strategies. Given the relatively minor history and lack of clear relationship between the lesion and symptoms, some may argue that the patient could be followed closely. However, the change in lesion and ventricles from the scan 5 years previously and the transependymal cerebrospinal fluid on MRI, all argue for treatment of hydrocephalus.

3. The basis for intervention is the transependymal migration of CSF seen on MRI, the clear progressive dilation of the ventricles over time, both of which suggest increasing hydrocephalus, and the probable growth of the mass over the time interval between the two imaging studies.

4. This patient could receive CSF diversion by means of a ventriculoperitoneal (VP) shunt. CSF diversion could also be performed by ETV. Consideration could be made for biopsy of the lesion at the time of ETV given the apparent location of the lesion in the posterior 3rd ventricle. It is not very likely that this lesion will progress and thus consideration for resection of this lesion would not be necessary absent progressive growth or unfavorable histology on biopsy.

5. ETV presents risks of late or early failure, fornix injury, intracerebral hematoma, hypothalamic injury, basilar aneurysm or arterial injury, and uncontrolled bleeding.

6. Technical considerations revolve specifically around the preferred option of ETV with lesional biopsy.

It would be essential that the ETV be performed first to make sure that this procedure was not aborted due to bleeding from the biopsy. Second to perform both the ETV and the biopsy a flexible endoscope would be needed.

Alternately, using a rigid scope, consideration must be given to placement of a single, slightly more anterior burr hole or two burr holes to allow an appropriate trajectory to both the anterior 3rd ventricle and ventriculostomy site and the posterior 3rd ventricle for the biopsy.

7. Expectations for the long-term control of hydrocephalus in this patient are good, approximately 80%. Typically tegmental, posterior 3rd ventricle lesions of this type are benign and slow growing and cause no further problems apart from the hydrocephalus. If a biopsy was performed, this may further define prognosis.

8. ETV with or without biopsy would be the best option followed by serial imaging observation of the mass lesion.

Case 5

1. Headache of the usual types (tension, migraine, etc.). Headache related to shunt malfunction. Headache related to overshunting. It is essential to consider shunt malfunction even in the presence of unchanged or small ventricles. It may be of benefit to know the details of her last shunt revision with respect to headache history and change seen on CT scan.

2. Diagnostic tests should first focus on establishing whether or not there is normal shunt function.

There are several strategies in this regard:

- Ophthalmology consultation might demonstrate papilledema missed on routine clinical exam.
- In the absence of this finding, this patient is not acutely ill and might be watched expectantly with migraine medication.
- However, with this strategy, lack of improvement in symptoms must provoke another look at the shunt.
- Repeat CT scan after 24 to 48 hours might show some change in ventricle size.
- Nuclear medicine shuntogram may be of some value. This test will include a shunt tap, which is a measure, though poor, of ICP at one moment in time. With good proximal reflux into the ventricle as an essential component of a normal test, some groups have reported this to be a reliable marker for shunt dysfunction.
- ICP monitoring over 24 to 48 hours may give an idea about the headache pattern and ICP management, which might prompt shunt or valve revision.
- Finally, a semiselective shunt exploration might demonstrate a poorly working component that could be replaced.

3. Early return of symptoms after shunt revision always prompts an appropriate workup for shunt malfunction.

A surgery can always convert a working shunt to a nonworking shunt. In the absence of any new signs of shunt malfunction, the same diagnostic possibilities as stated previously apply.

4. This patient needs an early-repeat CT scan. If there is still no change in her ventricles, the management could proceed according to Question #2.
5. At this stage, ICP monitoring becomes the best option.
6. Patients with VP shunts, new headaches, and no change in ventricular size on their CT scan can be broken down into four categories (variably described as part of the “slit ventricle syndrome”):
 - Shunt is malfunctioning despite CT findings – this can be determined by a shuntogram or shunt exploration, and the treatment is shunt revision.
 - Shunt is overdraining – ICP monitoring may be necessary, though clinical history can be helpful and upgrading of valve to a higher resistance setting would be the appropriate treatment.
 - Shunt is functioning maximally, but ICP is high anyway – this is rare and can only be really established with shunt exploration and ICP monitoring. In this rare instance, cranial expansion procedures would be the treatment of choice.
 - Not a shunt problem – established with normal ICP tracing with ICP monitor, and treatment is neurology and/or pain service consultation, and other medical management for chronic headache relief.

Case 6

Diagnosis: Various Brainstem Lesions.

1. Ischemia, infection, tumor, and phakomatose .
2. Acute brainstem ischemia, acute disseminated encephalomyelitis (ADEM), diffuse infiltrative brainstem glioma, and unidentified bright objects (UBOs) in neurofibromatosis.
3. D, B, C, and A.
4. The children in categories B (basal ganglia and thalami) and D (related to the neurofibromatosis) .

Comment

In children, many lesions may mimic primary brain tumors. A diffuse infiltrative brainstem glioma may have a long, benign course with only minimal clinical symptoms, significantly delaying diagnosis. In addition, symptoms may be

attributed to various other causes. Diffuse infiltrative brainstem gliomas have a very slow growth and respect functional neurological center for a long time. Hydrocephalus occurs usually late during the course of the disease. Acute brainstem infarction is rare in children and presents with an acute onset of severe neurologic deficits, including various cranial nerve palsies and frequently dysregulation of respiration, hypoventilation, and dysregulation of temperature control. Prognosis is poor; most children die in the acute phase or may progress into a locked in syndrome.

Acute brainstem infarction shows restricted diffusion on diffusion-weighted imaging and is usually symmetric in distribution. A thrombus within the basilar artery should be excluded. A mild mass effect may be observed because of the reactive edema. ADEM is an autoimmune reactive inflammation in response to a previous infection—frequently an upper respiratory tract infection.

Lesions are frequently multifocal and involve the brainstem, basal ganglia, and thalami. Symptoms may be acute and diffuse. On imaging, lesions are T2 hyperintense, ill defined, and show a mild mass effect. On diffusion weighted imaging, lesions usually show an increased diffusion compatible with vasogenic edema. If treated early, symptoms and lesions may resolve completely.

UBOs are seen in neurofibromatosis and are not yet completely understood. These lesions are benign and usually without any clinical symptoms related to their location, extent, and size. Lesions are ill defined and T2 hyperintense, may show mild mass effect, and infrequently show a contrast enhancement. Lesions may change over time or disappear completely. Diagnosis is made in the setting of a neurofibromatosis. Multiple additional lesions may be seen throughout the brain.

Case 7

Diagnosis: Cerebral Astrocytoma.

1. Ill defined, T2-hyperintense mass lesion within the left thalamus, internal capsule and basal ganglia, minimal contrast enhancement, multiple small cysts, minimal edema, mild obstruction of left lateral ventricle.
2. Cerebral astrocytoma.
3. A low-grade fibrillary astrocytoma.
4. Increased cholin and reduced N-acetylaspartate (NAA) concentration.

Comment

Cerebral astrocytomas are the most frequent supratentorial neoplasms in childhood. They represent more than 30% of all childhood supratentorial tumors. The majority of cerebral astrocytomas are fibrillary astrocytomas and may be of various degrees of malignancy; most of them are, however, low grade. Pilocytic astrocytomas are, with exception of a location within the hypothalamic-chiasmatic region, rare in a supratentorial location.

The tumor may be solid, solid with necrosis, or solid with multiple cysts. Tumors are frequently in a deep location involving the thalamus or basal ganglia and may extend into the mesencephalon. On magnetic resonance image, low-grade variants are typically T2 hyperintense and show minimal or no contrast enhancement. Because the lesion diffusely infiltrates the adjacent brain, tumor borders are usually ill defined. The mass effect can be minimal or significant and complicated by obstructive hydrocephalus because of a compression of the adjacent ventricles.

Higher-grade malignancies, especially a grade IV astrocytoma or glioblastoma multiforme, typically show a more extensive degree of contrast enhancement with big tumor cyst and extensive vasogenic edema. These lesions may be mistaken for abscesses. Diffusion-weighted imaging (DWI) is especially helpful in differentiating abscesses from tumor necrosis, because an abscess will be characterized by a restricted diffusion, whereas a necrotic tumor cyst will show an increased diffusion rate.

Currently, functional imaging, including DWI, diffusion tensor imaging, perfusion-weighted imaging, and 1H-MRS may help to characterize and determine the grade of malignancy of the tumor; however, a final histologic diagnosis is not yet possible. Tumor biopsy remains the gold standard for diagnosis. Therapy is determined by the location, age, and clinical symptoms. A deep, central location usually prevents surgical resection; a hemispheric location is more accessible for a surgical resection or at least tumor debulking followed by either chemotherapy and/or radiotherapy.

Case 8

Diagnosis: Medulloblastoma.

1. A large, solid, and contrast-enhancing tumor dorsal to the fourth ventricle; an

ill-defined dorsal tumor border with some edema within the vermis; and T2 hypointense with high cellularity.

2. Medulloblastoma dorsal to the fourth ventricle originating in the vermis.
3. Pilocytic astrocytoma, medulloblastoma, brainstem glioma, and ependymoma.
4. Residual tumor volume after neurosurgical resection.

Comment

Medulloblastoma is, depending on the age and gender of the patient, one of the most frequent primary neoplasms of the posterior fossa. Medulloblastoma is especially frequent in boys in their first decade of life. Overall, medulloblastoma (25%) is second to pilocytic astrocytoma (35%). Brainstem gliomas (25%) and ependymomas (12%) are the third and fourth most frequent tumors of the posterior fossa in children. In total, these four variants represent 97% of all posterior fossa tumors.

Medulloblastomas most frequently arise dorsal to the fourth ventricle either in the midline (vermis, 75% to 90%) or in a somewhat more lateral position (10% to 15%; also known as lateral medulloblastoma). Consequently, the fourth ventricle is pushed anteriorly and serves as an anterior tumor border.

The compression of the fourth ventricle may result in an obstructive hydrocephalus. Clinical symptoms are either related to the obstructive hydrocephalus or to local tumor infiltration and may include ataxia, gait disturbance, nausea, vomiting, and headaches. Medulloblastomas have a high cellularity and are consequently dense on computed tomography. On magnetic resonance imaging the lesions can be differentiated from ependymomas, which are typically located within the fourth ventricle (in contrast to the medulloblastomas, which are primarily located dorsal to the fourth ventricle).

Medulloblastomas usually display an ill-defined dorsal border because of infiltration of the adjacent vermis or cerebellar hemispheres; they are T1 hypointense to isointense and T2 isointense or hyperintense. Contrast enhancement may be strong but is occasionally absent. Cerebrospinal fluid (CSF) metastases may occur when the tumor has invaded the fourth ventricle. Tumor metastases may be seen within the third ventricle and lateral ventricles or along the spinal cord. A preoperative work-up should include the entire spinal axis. Prognosis depends on the residual tumor bulk after neurosurgical resection.

The smaller the residual component, the better the prognosis. The residual tumor component is even of higher prognostic significance than the initial tumor size.

In addition, the histology, immunohistochemistry, and neurogenetic results will also help to determine prognosis. Adjuvant treatment is decided by the combined information collected by imaging, immunohistochemistry, neurogenetic analysis, and residual tumor bulk after neurosurgery. Prognosis significantly improved in the last decade, with good long-term prognosis in most cases.

Case 9

Diagnosis: Semilobar Holoprosencephaly.

1. Fused frontal lobes, small lateral ventricles, lack of the anterior corpus callosum, unpaired anterior cerebral artery (azygos artery), hypoplastic falx cerebri, rudimentary temporal horns, and partial separation of the thalami.
2. Continuous fiber tracts between the fused frontal lobes and a horseshoe appearance.
3. Semilobar holoprosencephaly.
4. The ventral induction group of anomalies or the diverticulation or cleavage group of disorders.

Comment

A group of holoprosencephalies results from a disorder of diverticulation or cleavage. Holoprosencephalies are also known as disorders of ventral induction. Holoprosencephalies encompass an entire spectrum of malformations; the mildest form is septo-optic dysplasia; the most severe form is alobar holoprosencephaly. They both result from a failure of cleavage of the prosencephalic vesicle during organogenesis. Frequently, associated anomalies of the face are seen—"The face predicts the brain." Cyclopia has been described in cases of alobar holoprosencephaly.

Clinically, depending on the severity of the malformation, different symptoms may occur and include seizures, mental retardation, dystonia, microcephaly, hypothalamic-pituitary dysfunction, cyclopia, and fused metopic suture. Symptoms may be mild in lobar holoprosencephaly and severe in alobar holoprosencephaly. In septo-optic dysplasia, the anterior horns of the ventricles have a boxlike configuration on coronal MRI. In addition, an optic nerve pathologic abnormality is seen on funduscopy. Various degrees of hypothalamic-pituitary dysfunction are observed. In the lobar holoprosencephaly, a lobar brain is seen with hypoplastic frontal lobes, some

frontal horn formation, and the falx cerebri extends frontally. In semilobar holoprosencephaly, a partially formed falx cerebri and a partially formed interhemispheric fissure are seen in the posterior part.

The anterior brain is fused, the thalami are partially separated, and a small third ventricle and rudimentary temporal horns are demonstrated. The septum pellucidum is absent, the splenium of the corpus callosum is present, whereas the truncus of the corpus callosum is lacking. Hypoplastic olfactory bulbs and optic nerve may exist. In alobar holoprosencephaly, a small holosphere and monoventricle are seen, as well as fused thalami. However, no third ventricle, falx cerebri or corpus callosum, or interhemispheric fissure is seen.

In addition, no temporal horns are demonstrated, and malformations of the Willis circle are observed with an azygos or unpaired anterior cerebral artery. The prognosis is frequently poor, especially in the most severe forms of holoprosencephalies. Diagnosis is usually made prenatally by either ultrasound or fetal MRI. In septo-optic dysplasia, the prognosis will be determined by the associated malformations. In up to 50% of cases, additional lesions are identified by MRI. Postnatally, MRI is indicated to identify all details of the malformation.

Case 10

1. Medulloblastoma, ependymoma, pilocytic astrocytoma, choroid plexus papilloma, metastasis (although metastases are rare in children, in contrast to adults).

Medulloblastomas, constituting ~30% of all infratentorial tumors, are the most common malignant brain neoplasms of childhood, with a gender distribution showing male preponderance (1.4 to 4.8 times higher incidence in males).

2. MRI of the entire spine with and without contrast is also indicated to evaluate for drop metastases or “sugar-coating” along the spinal cerebrospinal fluid (CSF) pathways.

3. The origin of medulloblastoma is from the roof of the 4th ventricle. The World Health Organization (WHO) classification divides medulloblastomas into four histopathologic subtypes:

- Classic medulloblastoma
- Desmoplastic medulloblastoma

- Large cell medulloblastoma
- Medulloblastomas with extensive nodularity.

4. Maximal surgical resection along with chemotherapy and craniospinal axis radiation would be the indicated treatment. Gross total resection, when possible, can reduce the required radiation dose, with the caveat that the operative goal is not complete microscopic resection.

5. The surgical approach for resection of this tumor can be transvermian, transcortical, or telovelocerebellar, among others. Preoperative corticosteroids may help decrease peritumoral edema with any approach. In cases with ventricular dilatation, insertion of a ventriculostomy in the operating room, via either a coronal or occipital route, immediately prior to the tumor resection, can assist in achieving brain relaxation during the resection and managing CSF diversion following the resection.

6. The adjunct therapy would include chemotherapy (various regimens using cisplatin, vincristine, lomustine, and cyclophosphamide are commonly used) along with radiation.

7. • Standard fractionated radiation regimen for medulloblastomas consists of ~3600 cGy to the entire craniospinal axis with an 1800 cGy boost to the tumor bed.

- The so-called average – or standard – risk medulloblastomas (e.g., typical histology, extensively resected, nonmetastatic [M0], posterior fossa lesions in children older than 3 years) have a significantly higher 5-year progression-free survival (60–80%) with this treatment than high-risk tumors (e.g., anaplastic histology, extensive residual disease, metastases, or nonposterior fossa tumor location, and those diagnosed in children younger than 3 years) for which it is less than 40%.
- The neuraxis dose may be reduced to 2340 cGy with adjuvant chemotherapy in the average-risk group.
- Accordingly, reduced-dose radiation is usually not pursued in patients with high-risk tumors, and current studies are examining ways to improve longterm survival rates.
- Reduced doses of craniospinal radiation for the average risk group may thus diminish cognitive sequelae, although the extent to which doses can be safely reduced is currently undergoing study.

8. Less than half the patients require permanent CSF shunting. Shunt-related intraperitoneal tumor spread is a possible complication, but is rare.

9. The Chang system may be used for evaluating tumor grade in individual patients.

T1	Tumor <3 cm in diameter
T2	Tumor \geq 3 cm in diameter
T3a	Tumor >3 cm in diameter with extension
T3b	Tumor >3 cm in diameter with unequivocal extension into the brainstem
T4	Tumor >3 cm in diameter with extension up past the aqueduct of Sylvius and/or down past the foramen magnum (ie. Beyond the posterior fossa)
M0	No evidence of subarachnoid or hematogenous metastasis
M1	Tumor cells found in cerebrospinal fluid
M2	Intracranial tumor beyond primary site
M3	Gross nodular seeding in spinal subarachnoid space
M4	Metastasis outside the cerebrospinal axis (especially to bone marrow, bone)

According to the above system, an increase in tumor size and invasion of the brainstem define aggressive behavior of the tumor. These are classified as T1 to T4.

Several pediatric studies have shown that the M stage, the amount of residual disease after surgery and the age of the child are more predictive of outcome.

Extraneural disease is very rare, found in less than 2% of cases, and is most often in the bone marrow in the setting of widespread intracranial and spinal disease.

M stage:

Based on subarachnoid metastases, coding for the progressive appearance of tumor in cerebrospinal fluid (M1), in the cranium (M2) or in the spine (M3).

The M stage continues to be a highly significant prognostic factor in determining the intensity of therapy that is appropriate as well as predicting the outcome for the patient.

Case 11

1. The brain MRI demonstrates hydrocephalus.
2. After an intraventricular hemorrhage, the hydrocephalus is likely to be communicating (non-obstructive) because CSF circulation is blocked at the arachnoid granulations, causing the entire ventricular system to be enlarged. This is in contrast to non-communicating hydrocephalus (obstructive), where CSF circulation is blocked proximal to the arachnoid granulations, causing enlargement of the ventricles only proximal to the blockage.
3. In addition to enlarged ventricles, the absence of visible cerebral sulci, small sylvian fissures, and a thinned cortical mantle occipitally all suggest increased ICP.
4. Children with hydrocephalus have macrocephaly with increased head circumference. Additional signs may include bulging fontanelles, splayed cranial sutures, enlarged scalp veins, impaired upgaze, irregular respirations with apneic spells, and bradycardia. Common symptoms are irritability, poor head control, and poor feeding.
5. The best treatment for hydrocephalus in this patient is insertion of a ventriculoperitoneal shunt.

Case 12

1. The MRI shows a nonenhancing lesion best seen on fluid-attenuated inversion-recovery (FLAIR) study showing a medullary epicenter with minimal if any ventral lateral medulla identified on the right side. The lesion respects the boundaries of the medulla both caudally and rostrally.
2. Differential diagnosis includes benign or malignant brainstem tumor. Benign brainstem tumor is favored by the long history without multiple cranial nerve involvement, a respect of the boundaries of the medulla, and a medullary location as opposed to a pontine location. Benign masses in this location can include pilocytic astrocytoma. Less likely diagnoses include hemangioblastoma, pleomorphic xanthoastrocytoma, and a brain abscess. Malignant tumors in this location include glioblastoma multiforme, metastases, and lymphoma.

3. Important studies to obtain are swallowing studies, overnight sleep study, and vocal cord assessment by otolaryngology examination.
4. Given the probable benign nature of this lesion, despite its size based on clinical presentation and location, an initial approach should be to obtain a tissue sample (based on imaging studies, the tumor consistency appears to be different from the surrounding brainstem).
5. • The approach should be done in prone position with some neck flexion with the use of a suitable pediatric head frame to stabilize the head for surgery.
 - Obtaining accurate neuronavigation information is essential.
 - Additionally, multimodality evoked potential monitoring should be utilized.
 - The lesion should be approached through the eroded floor of the 4th ventricle, if such an area can be identified. Otherwise, relatively safe entry zones should be used.
 - Given the extension and size of the lesion on the left side, a far lateral approach may also present a less morbid option for resection of this tumor.
 - Given the finding and the presence of a presumably acceptable distinct appearance of the tumor, a significant debulking taking care to allow for reexpansion of compressed tissue should be done with careful monitoring of vital signs and evoked potentials.
 - If the walls of the lesion appear to show pulsations that would suggest thinning of the wall, particularly on the left anterior aspect, the procedure should be terminated. A significant but subtotal resection would be sufficient in this case.
6. A more expectant approach is also an option given the benign nature of the tumor (although we do not favor this option for the reasons stated above). Alternative treatment plans also include radiotherapy and chemotherapy. Both are associated with significant morbidity at this age and would not represent, at this point, a preferred option given the fact that the patient tolerated the surgery well.
7. Given the benign histology, the slow progression, and the fact that the brainstem is showing reexpansion, the prognosis, although guarded because of the location of the lesion, should be favorable. This also favors the possibility of further intervention and close follow-up. The preferred recommendation would be for return surgery through the same myelotomy approach into the brainstem. Some might recommend, prior to repeat surgery, chemotherapy in an attempt to reduce the tumor burden and then a second look at surgery. This has been advocated for choroid plexus papillomas, as well as some ependymomas.

Case 13

1. This child demonstrates typical findings for slowly progressive intracranial pressure in this age group. The reasons for this could be hydrocephalus, with mass lesion as a cause. Posterior fossa masses are common in this age group. Arachnoid cysts occur, postinfectious or hemorrhagic hydrocephalus also occurs, and in some children subdural hematomas present in this fashion (even as a result of nonaccidental trauma).

Benign macrocrania with benign enlargement of the subarachnoid spaces should not present with this constellation of developmental delay and neurologic exam findings.

2. This child needs urgent imaging. Ultrasound, computed tomography (CT) scan, or MRI scan are all reasonable options depending on the availability, though MRI is clearly the most definitive, and might be required regardless of the result of the other studies.

3. • The MRI shows a cerebrospinal fluid (CSF) density collection in the region of the suprasellar cistern and 3rd ventricle with associated obstructive hydrocephalus.

- Typically, arachnoid cysts of the suprasellar space may extend up and compress the 3rd ventricle and obstruct the foramen of Monro causing hydrocephalus.
- Arachnoid cysts of the 3rd ventricle may also appear with this pattern.
- Tumor cysts from craniopharyngioma or Rathke's cleft cysts may also be located in this region but should show a different density from that of CSF.
- Tumor cysts from hypothalamic astrocytomas should demonstrate a tumor mass in addition to a cystic component.
- Epidermoid or dermoid cysts should show a different density on fluid-attenuated inversion-recovery, but may also occur in this location.

4. Treatment options include

- Cyst fenestration, either open or endoscopic,
- Cyst shunting procedure.

5. Endoscopic fenestration might be the procedure of choice (open cyst fenestration via craniotomy usually has not worked to manage this condition). Endoscopic third ventriculostomy may also be done in the same setting. The risks for this include standard anesthesia risks, risks of infection, and significant bleeding; however, these are low risks as for all intracranial surgeries. Specific to this surgery, risks of incomplete fenestration of the cyst,

and recurrence of the cyst are possible. Cortical damage; intracranial hemorrhage; risk of seizures; damage to the fornix, the hypothalamus, or the basilar artery; or other uncontrolled intraventricular bleeding are also important risks to consider.

6. The chance of success of this procedure is difficult to assess. Standard endoscopic third ventriculostomy for obstructive hydrocephalus might have a success rate as low as 40% in this age group, but successful fenestration of this cyst should have a more reliable duration of effectiveness.

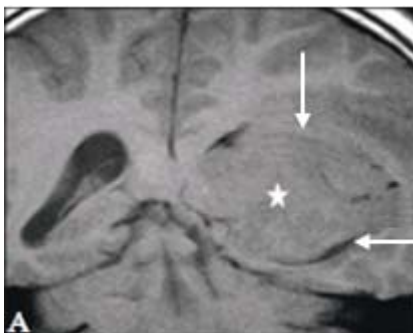7. If the initial procedure fails, open fenestration is an option, but the surgical approach is not without significant potential morbidity. Cystoperitoneal shunting of the cyst should relieve the obstructive hydrocephalus and would be the procedure of second choice.

Case 14

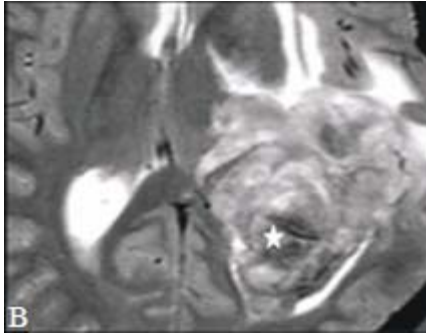
- | | |
|--------------------------|---|
| 1. Thalamostriate vein | G |
| 2. Septal vein | A |
| 3. Choroid plexus | H |
| 4. Anterior caudate vein | F |
| 5. Fornix | E |
| 6. Caudate nucleus | D |
| 7. Septum pellucidum | B |
| 8. Choroid fissure | C |

Case 15

1.



(A) Coronal non-contrast T1WI through the trigone/occipital horns. There is a large isointense mass within the left trigone and occipital horn (star). There is blurring of the superior and lateral margins of the left trigone (arrows).



(B) Axial T2WI. There are hypointense areas within the posterior aspect of the mass (star) suggesting either calcifications or blood products. There is surrounding vasogenic edema anteriorly. There is no clear separation between the tumor and the anterior and lateral walls of the trigone suggestive of infiltration.

(C) Axial post-contrast T1WI. The mass is avidly contrast enhancing and lobulated with clearly defined margins. There is however possible infiltration of the anterolateral walls where the parenchymal vasogenic edema exists. There is local mass effect.

2. Choroid plexus carcinoma (CPC), choroid plexus papilloma (CPP), intraventricular meningioma, metastatic carcinoma.

3. Choroid plexus carcinoma (CPC) WHO III.

4. Yes. At the time of diagnosis, it is estimated that over two-thirds of the cases already have CSF dissemination of tumor. It is therefore essential to obtain MRI of the craniospinal axis to exclude distant metastasis so as to better plan how to proceed with management.

5.

- Location, number if more than one, size of lesion, and presence of distant subarachnoid space contrast enhancing lesions.
- Hydrocephalus if present.
- Need to evaluate the remainder of the central nervous system (CNS) to exclude CSF dissemination.
- If follow-up, presence of residual tumor or metastases.

Comment

CPC on MRI is usually a large intraventricular mass with heterogeneous intensity pattern on T2WI and GRE because of the presence of calcifications and hemorrhage. It is usually isointense on T1WI, has irregular lobulated margins with surrounding parenchymal brain infiltration, perilesional edema, and avid contrast enhancement.

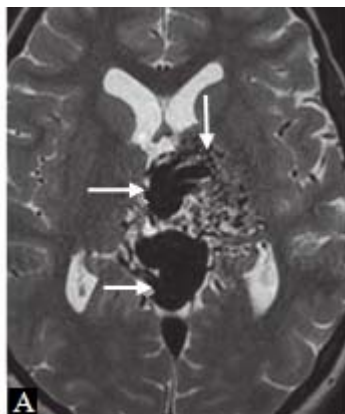
Hydrocephalus is common, and distant subarachnoid space enhancing masses indicate tumor seeding which may occur in about two-thirds of these patients at diagnosis. Systemic metastases have also been reported in long survivors. These features are rare in choroid plexus papilloma (CPP) or meningioma. Metastatic

tumors tend to be multiple, but solitary lesions can occur. About 50% of CPC are found in the lateral ventricles, 40% in the fourth ventricle, and 5% in the third ventricle with the remaining 5% involving more than one ventricle. Calcifications and hemorrhages impart heterogeneity to the hyperdense mass on NCCT. Areas of necrosis are hypodense on NCCT. It shows avid contrast enhancement and infiltration of ventricular wall with surrounding hypodense edema. It is a highly vascular tumor.

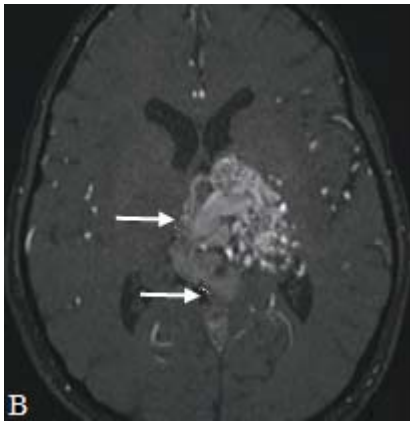
CPC is a WHO III tumor with about 80% occurring in children where it constitutes between 20% and 40% of all choroid plexus tumors and almost all occurring in children between 2 and 4 years. CPC is generally more common in males with a male to female ratio of 1:1 in the lateral ventricles and 3:2 in the fourth ventricle. Because of the propensity to obstruct the cerebrospinal fluid (CSF) pathway, symptoms and signs of hydrocephalus are the most common presenting symptoms. Infants may present with large heads. Headache, vomiting, and visual problems due to raised intracranial pressure are common. Familial CPC occurs in families with germline TP53 mutations, clustering of cancer suggestive of Li-Fraumeni syndrome, rhabdoid predisposition syndrome, and germline INI1 mutation to name a few. CPC grows rapidly with a rather poor prognosis. It is recommended that the tumor be totally removed with gross total resection achievable in only 40% to 50%. There is a 5-year survival rate of 40%. Adjuvant treatment with chemotherapy and/or radiation remains controversial.

Case 16

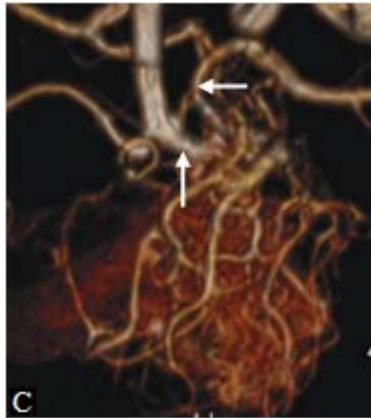
1.



(A) Axial T2WI through the thalamus. There is a collection of tubular signal voids in the left thalamus (vertical arrow) extending into a large tortuous signal void in the midline consistent with a large internal cerebral vein and great vein of Galen (transverse arrows). Areas of hyperintensity are seen surrounding the tubular signal voids in the left thalamus. These areas possibly represent gliosis.



(B) Axial 3D TOF MRA source image through the thalamus. There is a collection of serpentine tubular structures in the left thalamus. Large tortuous internal cerebral vein and vein of Galen are visualized (arrows).



(C) Volume-rendered 3D TOF MRA best projection. There is a left thalamic tangle of vessels (the nidus) with many larger feeding arteries from the enlarged left P-Com artery and the left posterior cerebral artery (PCA) (arrows).

2. Arteriovenous malformation (AVM), vein of Galen aneurysmal malformation (VGAM).
3. Left thalamic AVM.
4. Complications of AVM include accelerated atherosclerosis on afferent arteries, hemorrhage, mass effect, volume loss, hydrocephalus, dementia, and high cardiac output failure.
5.
 - Location, size, and number if more than one.
 - Pattern of afferent and efferent vessels regarding origins, number, stenosis, and aneurysms.
 - Evidence of prior hemorrhage or new hemorrhage.
 - Presence of steal phenomenon, gliosis, atrophy, calcification, mass effect, hydrocephalus, etc.

Comment

Both MRI and CT are complementary in the evaluation of AVM. MRI, however, presents comprehensive topographical and parenchymal details unmatched by CT. CT, however, is better at distinguishing between calcifications and hemorrhage. CTA and MRA are equally effective in evaluating the afferent, nidus, and efferent vascular patterns of the AVM. The classic AVM has afferent vessels or arteries that are usually larger than other arteries in the vicinity. There is a nidus that contains a tangle of small vessels

that are hyperdense on CT and show signal voids on T2WI, some of which could dilate into aneurysmal proportion. T2 hyperintense areas present within the nidus probably represent gliosis. Calcifications and old and new hemorrhages could be present. Calcification and acute hemorrhage are usually hyperdense on CT but could be differentiated by measuring the Hounsfield unit. Both may be hypointense on T2WI and GRE. Surrounding volume loss due to steal phenomenon or edema due to recent bleed would be visible. The draining or efferent veins are also usually larger than other veins in the vicinity. The afferent and efferent vessels could be single or multiple. Accelerated atherosclerotic changes on the afferent vessels could result in irregularities, stenosis, or aneurysmal formation that would alter the flow dynamics of the AVM. The details of the vasculature are well demonstrated by CTA or MRA. DSA now plays a role in endovascular treatment of AVM, with the primary diagnosis being made by CT/CTA and MRI/MRA. The DSA confirmed in this case that most of the afferent supply was from the left thalamoperforators. Strategically placed AVM could produce mass effect and hydrocephalus. The presence of a parenchymal nidus indicates an AVM draining into the vein of Galen rather than VGAM.

AVMs are rare and considered congenital but de novo AVMs are reported. They have been described in all age groups. Common presentations include headache, numbness, neurologic deficit, intracranial hemorrhages (subarachnoid hemorrhage [SAH], intracranial hemorrhage [ICH], and intraventricular hemorrhage [IVH]), mental status changes, and coma. The risk of hemorrhage depends on the hemodynamics of the AVM, its location, and the presence of prior hemorrhage. This risk is estimated at 1% to 4% per year. In rare situations, AVMs could thrombose spontaneously. Multimodal treatment is usually advocated. This includes endovascular treatment, radiosurgery, and surgical intervention.

Case 17

1.

(A) Sagittal T1WI. There is a well-circumscribed T1 hypointense subgaleal mass over the anterior fontanel (arrow). (B) Coronal T2WI through the mass. The mass is hyperintense (arrow). The lesion did not restrict diffusion nor contrast enhance (not shown).

2. Sebaceous cyst, epidermoid cyst, dermoid cyst.

3. Subgaleal dermoid cyst.

4. Classically, dermoids are found at the midline, whether intracranially or extracranially. In the case of a subgaleal dermoid, the region of the anterior fontanel is a favored location. Subgaleal dermoids may also occur offmidline. Dermoids may have a fatty internal consistency, which can help to distinguish them from epidermoids.

Epidermoids, on the other hand, can show restricted diffusion, perhaps reflecting the presence of ordered layers of keratin filament.

5.

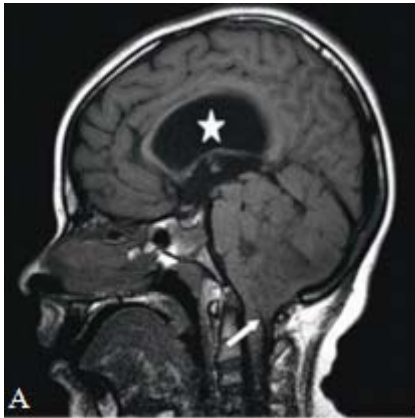
- Subgaleal inclusion cysts are benign lesions which arise from mild anomalies of neural tube closure.
- These lesions are easily treated at surgery with good outcomes. They do not imply the presence of other more significant neural tube anomalies.
- Location and size.

Comment

Congenital inclusion cysts occur as a result of imperfect partitioning of ectodermal elements, particularly involving sites of neural tube closure, during embryonic development. Most commonly, these present as intracranial lesions, but when extracranial, they arise in the subgaleal space. Histologically, two types are recognized. Those cyst composed exclusively of epidermal lineages are referred to as epidermoid. These are fluid density on CT, hyperintense on T2WI, and generally isointense on T1WI. They contain epidermal cells and keratinous debris. Dermoids, by contrast, contain epidermal as well as dermal elements including hair follicles, sebaceous, and apocrine apparatus. On CT, dermoids can be less dense than fluid, reflecting the presence of fatty sebaceous secretions. For the same reason, they may be hyperintense on T1WI, though this is not obligatory. On T2WI, variable and heterogeneous signal is typical. Neither epidermoid nor dermoid cysts enhance centrally, though either may show mild rim enhancement.

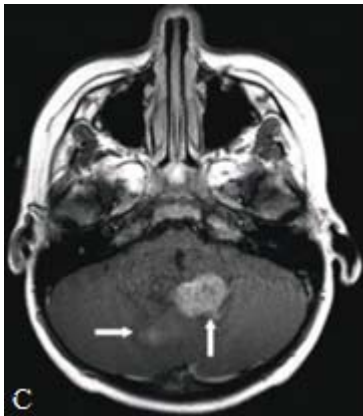
Case 18

1.



(A) Sagittal T1WI. The mass is within the fourth ventricle, with extension of tumor through the midline foramen of Magendie (arrow). Notice stretching of the corpus callosum, indicating hydrocephalus (star).

(B) Axial T2WI through the mass. The lesion is heterogeneous with some cystic foci.



(C) Axial post-contrast T1WI through the mass. There are areas of enhancement (arrows) within the mass.

2. Medulloblastoma, ependymoma, choroid plexus papilloma.

3. Ependymoma.

4. Ependymal rest cells can be found anywhere in the periventricular region and even somewhat removed from the ventricle. On rare occasions, ependymomas may even appear to be entirely parenchymal. These are usually supratentorial in location. More typically, posterior fossa ependymomas are often described as arising from the floor of the fourth ventricle. This results in a tumor with a sharp interface along the ventricle roof. On the other hand, medulloblastoma, which would be high on the differential whenever ependymoma is considered, is described as arising from the fourth ventricle roof, giving a sharp interface with the ventricular floor.

5.

- Ependymoma is one of several tumors arising within the posterior fossa, often in children or young adults.
- Imaging findings can be suggestive of the diagnosis.

- There is overlap between the appearances of posterior fossa tumors, and therefore, a differential diagnosis should always be given.
- Presence of complications such as herniations, CSF dissemination, and hydrocephalus.

Comment

Ependymoma is a tumor derived from ependymal rest cells. Most are infratentorial and within the fourth ventricle. They are usually well defined and shown very heterogeneous characteristics on both CT and MRI, reflecting the presence of tumoral hemorrhage or cysts and calcifications. Supratentorial ependymomas tend to exhibit more cystic component than their posterior fossa counterpart. Enhancement is variable, but most do enhance to some degree.

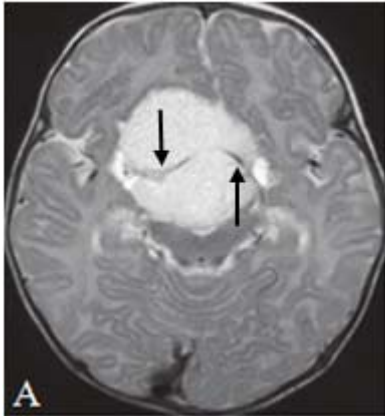
There is usually very little or no perilesional edema. Classically, ependymoma is described as a plastic tumor in that it can insinuate itself and extrude, almost like toothpaste, through small spaces such as the foramina of Luschka and Magendie. When present, this is a very helpful imaging sign to discriminate it from the other posterior fossa masses listed in the differential diagnosis.

Ependymomas are designated WHO II and III tumors, and there is no definite imaging way to separate WHO II lesion from the anaplastic tumor except that grade III lesions are more likely to contrast enhance. The histologic criteria are also very uncertain. The difference is in their biologic and clinical behaviors. The anaplastic lesion grows rather more rapidly causing raised intracranial pressure early in the disease. SV40 virus strain has been identified in ependymomas, raising the possibility of an association with this infection. Ependymomas have no gender preference.

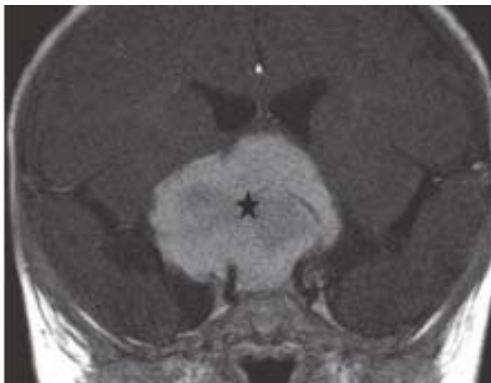
Posterior fossa ependymomas are more common in children than adults and invariably present with features of hydrocephalus and raised intracranial pressure such as headache, nausea, and vomiting. Macrocrania is a feature in children under the age of 2 years. Children with posterior fossa ependymomas fare worse than their adult counterpart principally because of the location of their tumors in the posterior fossa and increased incidence of anaplasia. Incomplete resection and cerebrospinal fluid (CSF) disseminations are poor prognostic factors.

Case 19

1.



(A) Axial T2WI through the mass. The mass is homogeneously hyperintense. The lines seen at the lateral aspect of the mass are the bilateral A1s being elevated (arrows).



(B) Coronal post-contrast T1WI through the mass. The mass (star) enhances relatively homogeneously throughout.

(C) Photomicrograph shows radial perivascular arrangement of piloid glial cells (H&E stain).

2. Glioma, meningioma, lymphoma, pituitary adenoma, craniopharyngioma, pilomyxoid astrocytoma (PMA), pilocytic astrocytoma (PA).

3. PMA.

4. PMA requires a more aggressive treatment. Recurrence rate is higher, and overall survival is shorter than in PA.

5.

- Location.
- Presence of mass effect or hydrocephalus.
- Presence of leptomeningeal disease may prompt craniospinal axis evaluation.

Comment

The suprasellar region is the commonest location of PMA and occurs in about two-thirds of the cases. PMA may occur elsewhere in the CNS. This case is that of a solid suprasellar PMA as are most of these tumors showing homogeneous hypointensity on T1WI and hyperintensity on T2WI with homogeneous contrast

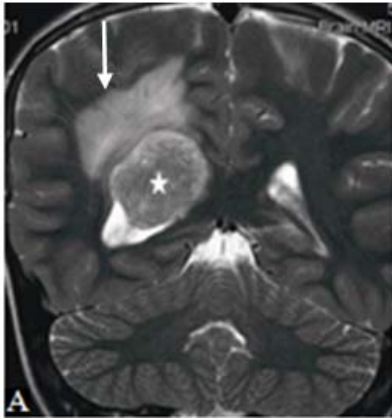
enhancement. Mixed intensity pattern with heterogeneous contrast enhancement may occur in a mixed solid and cystic tumor. There is generally elevated apparent diffusion coefficient (ADC). GRE may demonstrate hemorrhage in up to 20%, and calcification is very rare. PA shares a lot of features in common with PMA from which it may be difficult to differentiate. PMAs compared with PAs have been found to have more solid nonenhancing areas, higher ADC, and higher T2WI signal intensity. The higher ADC and T2WI signal intensity likely reflects the myxoid component.

A more heterogeneous lesion particularly with hemorrhage may be difficult to distinguish from craniopharyngioma. Other suprasellar tumors such as glioma, lymphoma, meningioma, and suprasellar extension of macroadenoma may pose a difficult diagnostic challenge. When lesions are larger it can be difficult to tell exactly where they are arising. A meningioma or any highly cellular mass, such as lymphoma, are usually isointense to hypointense on T2WI. The high cellularity of these lesions usually results in lower ADC value or restricted diffusion, and this lesion has elevated ADC values. A meningioma may present with a dural tail which is absent in this case. Lack of sella enlargement excludes pituitary macroadenoma.

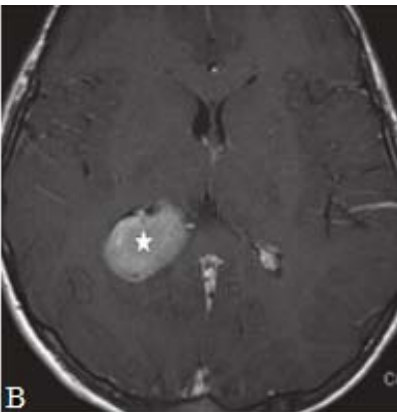
PMA, a WHO II astrocytoma, is a tumor usually seen in children and young adult. PMA is a localized glioma with piloid cells and myxoid background. A characteristic finding is perivascular arrangement of its cells. Rosenthal fibers, eosinophilic granular bodies, and microcysts are usually not seen. Necrosis and parenchymal infiltration are more common. PMA often occurs in the hypothalamic and chiasmic region, but they can occur in any part of the CNS. The lesions may have lobar presentation with a propensity for the temporal lobes. Secondary to the predominant location in the third ventricular region, many of the cases present with hydrocephalus and symptoms of increased intracranial pressure (headache, nausea, vomiting). Other symptoms include failure to thrive, confusion, ophthalmoplegia, facial weakness, extremity weakness/hemiplegia, and seizure when cortical. PMAs are associated with long survival even when partially resected. PMA has a higher rate of recurrence and CSF dissemination compared with PA.

Case 20

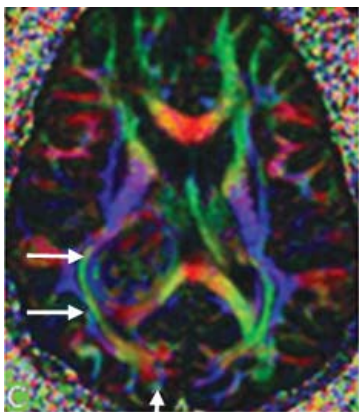
1.



(A) Coronal T2WI through the mass. Mass (star) is mildly heterogeneous but isointense to GM. Peripherally superiorly and medially the mass is as hyperintense as the adjacent periventricular hyperintense vasogenic edema (arrow).

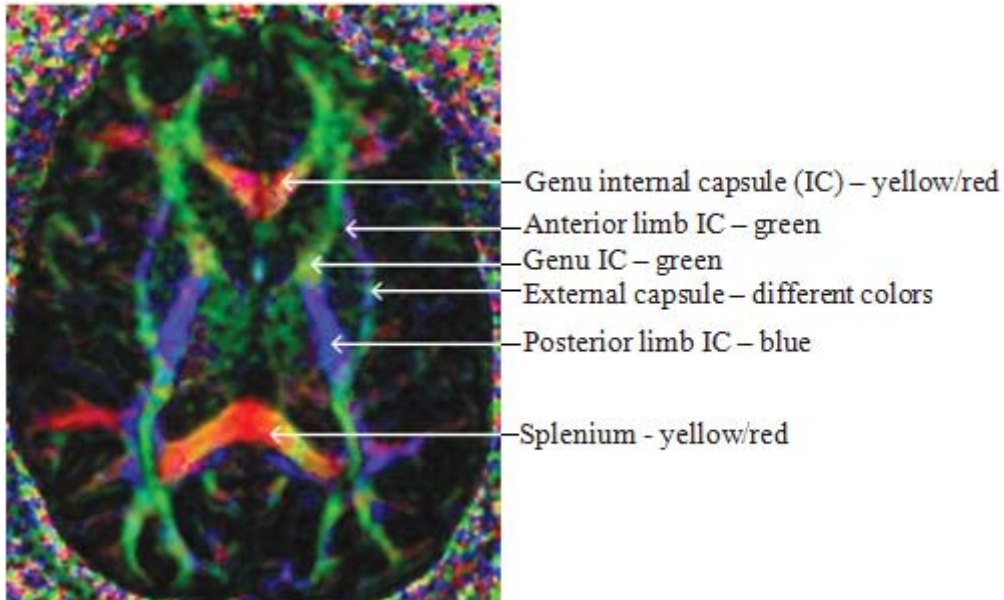


(B) Post-contrast T1WI. There is homogeneous contrast enhancement of the smooth margined mass (star).



(C) DTI color directional map. The color hue indicates direction of fiber tracts: green indicates anteroposterior direction; blue indicates craniocaudal or superoinferior direction; red indicates left to right direction.

There is mass effect on the right inferior fronto-occipital fasciculus and inferior longitudinal fasciculus (transverse arrows) which have been compressed laterally. There is also posterior displacement of the fibers in the right splenium with disorganization of the right forceps major (vertical arrow).



Level of the basal ganglia. The anterior limb of the internal capsule (IC) is green because of the anteroposteriorly directed frontopontine and thalamocortical tracts. The posterior limb of the IC is blue because of the superoinferiorly directed corticospinal, corticospontine, and corticobulbar tracts traveling down the centrum semiovale and corona radiata. The external capsule color varies from green posteriorly to blue anteriorly because of the direction of the various components. The splenium and genu of the corpus callosum have a red hue centrally (left to right direction), while lateral segments are yellow or mixed color in view of the different directions of the fiber tracts.

2. Choroid plexus carcinoma (CPC), choroid plexus papilloma (CPP), intraventricular meningioma, ependymoma.

3. Intraventricular meningioma.

4. Bilateral vestibular schwannomas are the hallmark of NF2. Other tumors include schwannomas of the trigeminal nerves, and gliomas which include ependymomas and astrocytomas (mostly pilocytic). Other nontumoral intracranial lesions may include menigioangiomas and cerebral calcifications.

5.

- Location and size of tumor.
- Effect on surrounding structures.
- Presence of hydrocephalus.
- Differential diagnosis.

Comment

Like most meningiomas, intraventricular meningioma has unique imaging features on MRI. It is mostly isointense to GM on T1WI and isointense to

hyperintense on T2WI, usually smooth margined and avidly contrast enhancing. Calcifications impart some heterogeneity to the signal pattern with multifocal hypointensities on T2WI.

Meningiomas generally exhibit local mass effect dilating the ventricle and compressing adjacent structures but rarely producing perilesional edema as in this case. DTI may show attenuation of surrounding fiber tracts and reduced Fractional Anisotropy (FA). The trigone is the most common location of intraventricular meningioma. About 77.8% of intraventricular meningiomas occur in the lateral ventricles closely followed by the third ventricle in 15.6% and the fourth ventricle in 6.6%. On NCCT meningiomas are isodense to slightly hyperdense with avid contrast enhancement following contrast administration. Angiogram usually shows increase vascularity and tumor blush with most of the supply coming from the posterior choroidal artery and some from the anterior choroidal artery. CPP is usually lobulated, more heterogeneous on T2WI with flow voids, and more frequently associated with hydrocephalus even when it is not obstructing the CSF pathways. CPC is more poorly margined with a tendency to infiltrate ventricular walls and cause perilesional edema. Ependymomas are generally more heterogeneous in signal characteristics and avidly contrast enhancing.

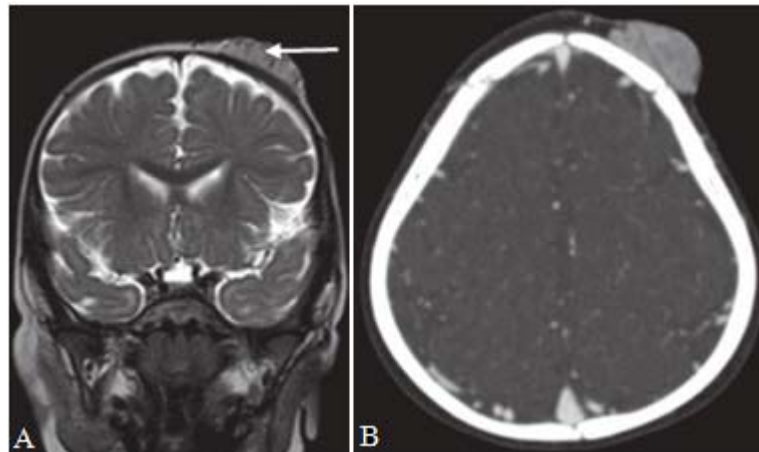
Intraventricular meningioma is rare accounting for between 0.5% and 3% of all intracranial meningiomas. Meningiomas are designated WHO I tumors with very few histologic subtypes atypical WHO II or anaplastic WHO III.

NF2-associated meningiomas have a higher mitotic index and a more aggressive clinical behavior than sporadic meningiomas. All histologic subtypes of meningiomas have been reported within the ventricles. They are more common in adults than in children except in NF2. There is no gender preference unlike hemispheric meningiomas that are more common in females. Clinical presentation is usually not specific and may include headache, mental status changes, focal neurologic deficit, vertigo, and gait disturbance.

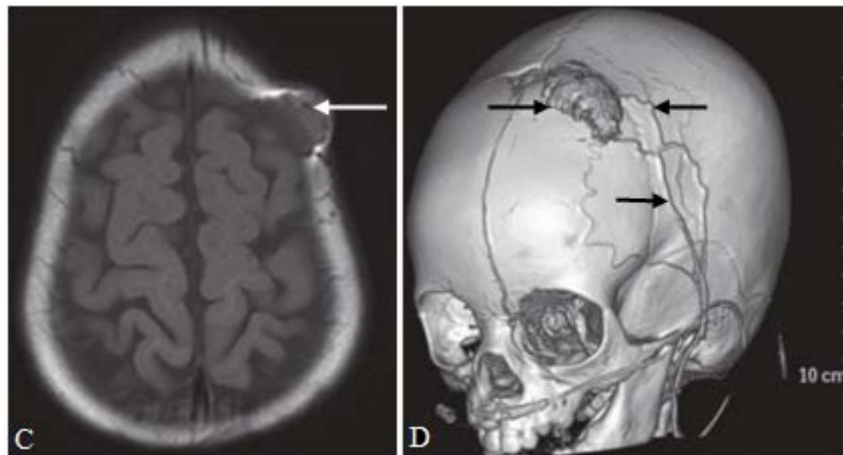
Intraventricular meningiomas tend to grow very large before presenting because of the vague symptoms unless it is situated where it could obstruct the CSF pathways. Total excision by piecemeal reduction in tumor volume with ultrasonic aspiration has been advocated as providing a safe surgical treatment and providing cure.

Case 21

1.



(A) Coronal T2WI through posterior frontal bone. There is a left frontal scalp mass, mildly hyperintense to brain, with dark foci suggesting flow voids (arrow). (B) Axial T1WI through the lesion. The mass is isointense to brain (arrow).



(C) Axial CTA source image. There is diffuse enhancement of the mass. The underlying bone appears intact. (D) Volume rendered CTA. The lesion vascular supply is from branches of the external carotid artery (ECA) (arrows).

2. Congenital hemangioma (CH), infantile hemangioma (IH), vascular malformation, hemangioendothelioma.

3. Infantile hemangioma (IH).

4. Hemangioma of bone (vascular malformation, may be capillary or cavernous based on size of vessels); cavernous hemangioma of the brain (vascular hamartoma prone to intralesional hemorrhage); IH; CH; hepatic cavernous hemangioma (benign network of vascular channels); hemangioendothelioma (malignant vascular tumor of the skin and organs).

5.

- IH is a common benign lesion which is best left along.
- Definitive therapy should be considered when mass effect threatens critical structures or when skin ulceration is seen.
- Extent and other associations such as in PHACES syndrome—posterior fossa malformation, hemangioma, arterial anomalies, cardiac anomalies/aortic coarctation, eye abnormalities, and sternal defects.

Comment

IH in the head is mostly cutaneous in location. It presents on CT as a well-defined soft tissue mass confined to the scalp that enhances moderately to strongly. It may displace but usually does not invade structures. MRI is the examination of choice for evaluation of the total geography of IH. MRI tends to show isointense mass with flow voids and avid contrast enhancement on all spin echo sequences. Ultrasound has been used to differentiate IH from other cutaneous cystic lesions or lymph nodes. It is limited in its ability to map the extent of the lesion. It could grow to a rather large size.

IH is a true neoplasm of vascular endothelial origin as opposed to a vascular malformation. Up to 10% of Caucasian infants are affected. The tumor may arise anywhere, but the head and neck regions are most common. When superficial, the tumor appears as a bluish-red, noncompressible mass with the surface texture of a strawberry. The classic IH is small or undetectable at birth and develops rapidly during the first year of life. The tumor demonstrates a two-phase life cycle. Initially, during the proliferative phase, the tumor grows rapidly and is highly vascularized. Histologically, endothelial cell hyperplasia predominates. During the subsequent involutive phase, the endothelial cells thin with deposition of fibrofatty material. Complete or near-complete regression is the norm within 5 to 7 years. IH is contrasted to CH, a histologically similar lesion but with a different natural history. CHs are present and fully formed at birth.

By clinical examination and imaging, they appear similar to IH. CHs follow two possible life cycles. Some will undergo rapid involution with complete regression in 1 to 2 years. Others are noninvoluting and not only persist with time but actually grow as the child grows. Pharmacotherapy with corticosteroids and propranolol appears to be a safe and effective treatment when treatment is deemed necessary. Laser surgery and surgical excision are other treatment options.

References

1. H. Hasegawa, M. Crocker, P.S. Minhas. Oxford Case Histories in Neurosurgery, Oxford University Press, Oxford, UK, 2013.
2. N. D. Kitchen, H. Manji, G.M. McKhann II. Self-Assessment Colour Review of Clinical Neurology and Neurosurgery, Manson Publishing Ltd, London, UK, 2003.
3. T.G. Psarros, S.P. Moore. Intensive Neurosurgery Board Review. Lippincott Williams&Wilkins, Philadelphia, 2006.
4. R. Nader, A.J. Sabbagh. Neurosurgery Case Review. Questions and Answers. Thieme Medical Publishers, Inc., New York, Stuttgart, 2010.
5. M.F. Omojola, M. Castillo. Neuroimaging: A Teaching File. Wolters Kluwer Health, Philadelphia, 2015.